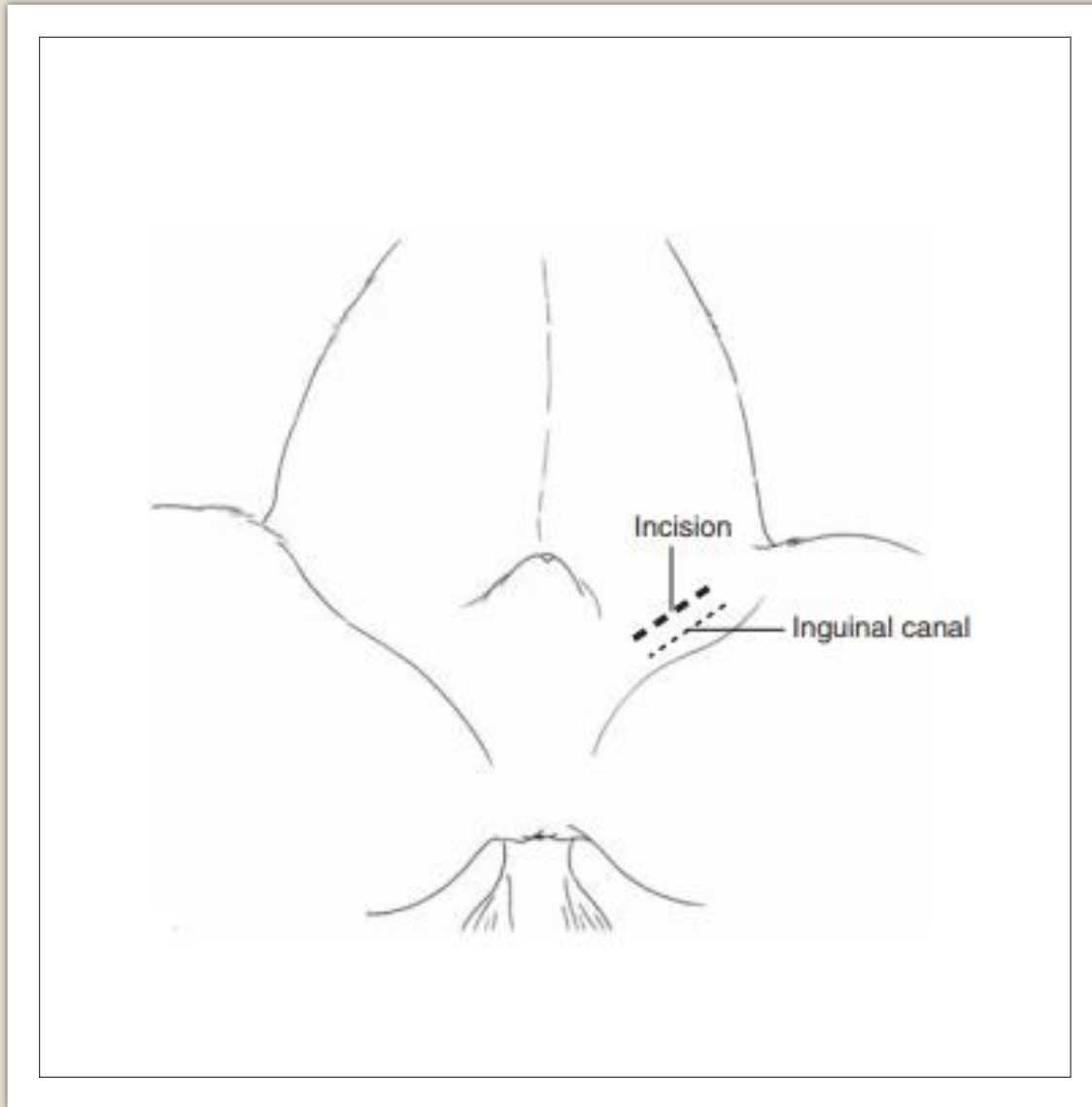




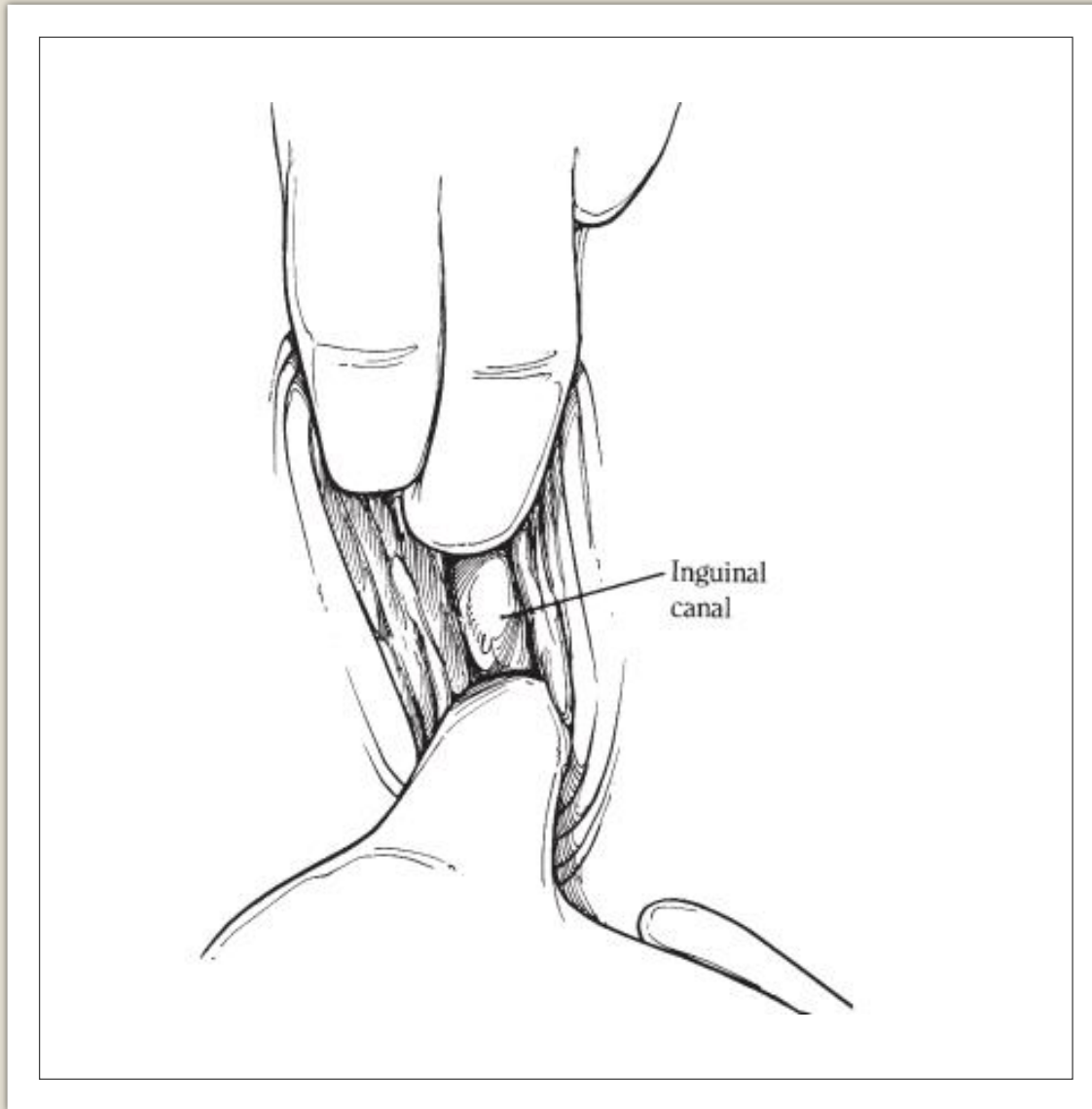
PARAINGUINAL APPROACH



STEPS INVOLVED

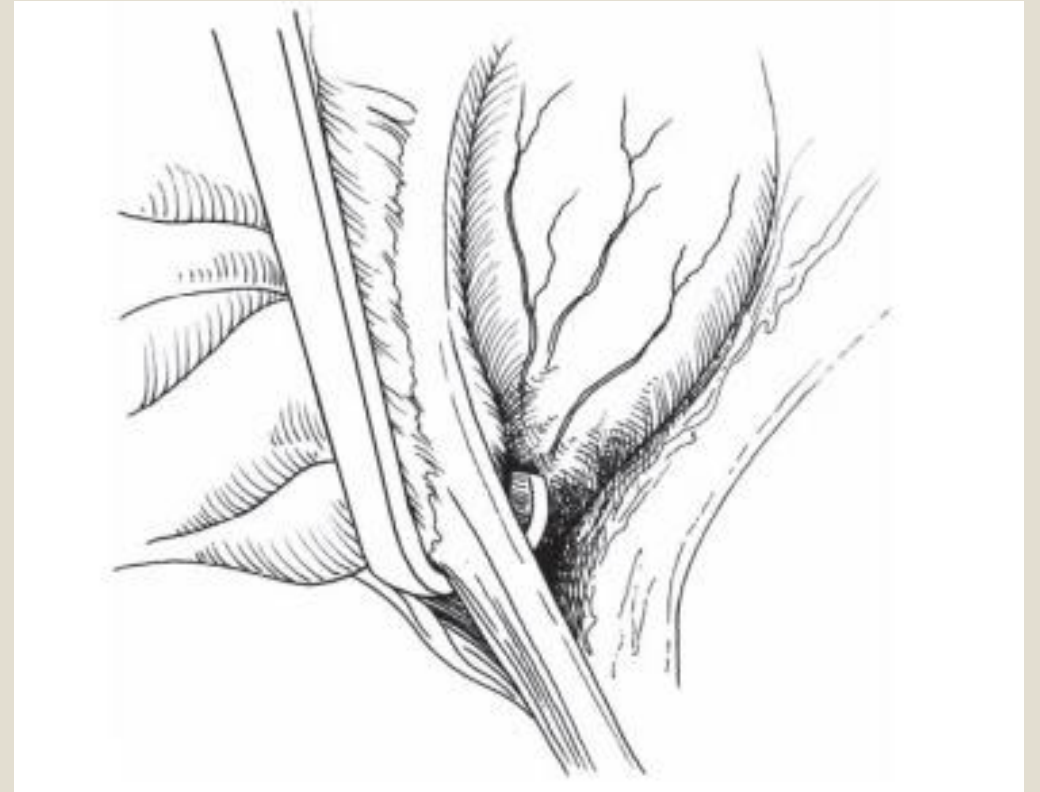



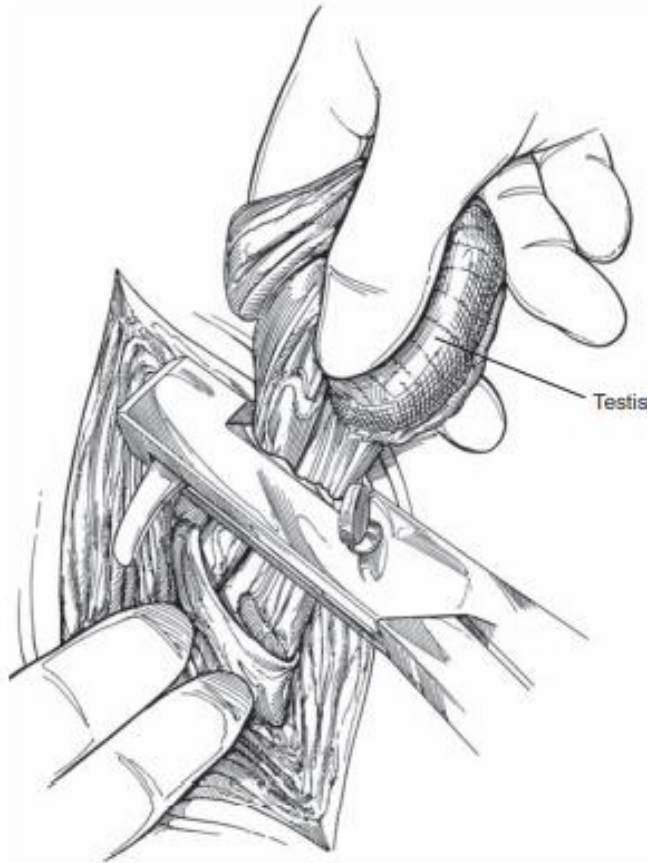
- Make a 10-cm incision to allow access to the inguinal areas. The 10-cm incision is made through the skin parallel to and 4 cm axial to the inguinal canal.



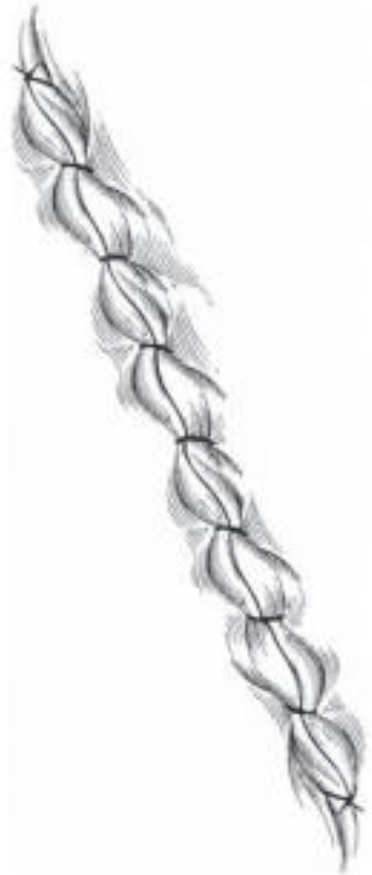- The inguinal canal can be explored as for the inguinal approach, to assess the presence of an inguinal testis. If there is an inguinal testis, remove it. If no inguinal testis is present, make an incision of similar length into the external rectus sheath using a scalpel blade. Ensure to not make the incision any deeper than the sheath.

- Bluntly divide the rectus abdominus muscle, and bluntly penetrate the internal rectus sheath along with the peritoneum. Place a spay hook through the incision into the peritoneal space. Sweep the tip of the spay hook through the region of the vaginal ring to pick up the gubernaculum.





- Remove The gubernaculum from the abdomen and place traction until the testis is removed from the abdomen. The testis is emasculated



- Close the external rectus sheath using simple continuous pattern using no. 1 polyglyconate.
- Close the subcutaneous tissue and skin respectively using a no. 2-0 synthetic absorbable suture material using a simple continuous pattern.

Reference

- Hendrickson D. Techniques in Large Animal Surgery. 3rd ed. Ames: Blackwell Publishing;.