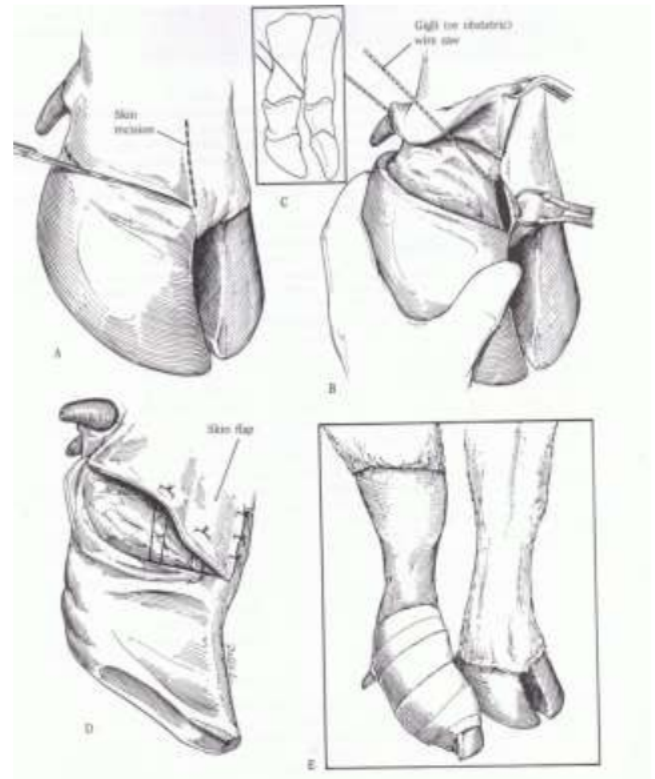
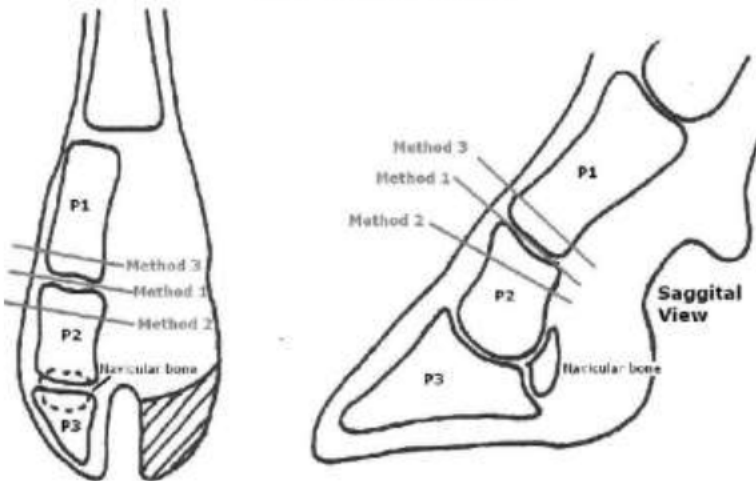


Skin Flap Attempted Closure Technique

- Method 1:** Disarticulation of the distal interphalangeal (DIP) joint
Method 2: Amputation through proximal Phalanx 2 (P2)
Method 3: Amputation through distal Phalanx 1 (P1)

Figure 1: Amputation Sites



1. The skin incision is made along the abaxial and axial surface of the coronary band
 - a. The skin incision on the axial surface is made first so as not to obscure the surgical field with blood. The skin is then dissected free from the underlying digit, and one attempts to save as much of the skin flap as possible.
 - b. Alternatively, a circumferential skin incision can be made in a similar plane to the wire cut illustrated in picture 2- C.
2. Vertical incisions are made cranially and caudally
3. The skin and subcutaneous tissues are incised to the bone.
4. The amputation may be performed in two locations.
 - a. A low amputation is performed when only the coffin joint and distal phalanx are diseased; this amputation is directed through the middle phalanx.
 - b. A high amputation (**described technique**) , which is used in cases with involvement of the coffin joint, distal phalanx, pastern joint, and middle phalanx. This amputation is directed through the junction of the middle and distal third of the proximal phalanx.
5. An obstetric saw (or gigli) is placed in the incision in the interdigital space.
6. The amputation is commenced with the wire saw directed parallel to the long axis of the limb until the wire is located at the distal end of the proximal phalanx.

- a. The saw is directed perpendicular to the long axis of the proximal phalanx to seat the wire in the bone, and then the position of the wire is directed so it is approximately 45° to the long axis of the proximal phalanx .
7. Once the digit has been removed, excess interdigital adipose tissue and all necrotic tissue, especially that involving the tendons and tendon sheaths, should be dissected sharply from the wound.
 - a. If the digital artery can be located, it should be ligated.
8. Some of the skin flap may be sutured down, but when the surgical site is swollen from infection and when some skin necrosis is present in the region, then this is not usually possible.
 - a. Complete closure is contraindicated because infection will resolve more rapidly if the skin flap is not completely sutured, to allow better ventral drainage .
 - b. The value of skin flaps and of any attempt at closure has been questioned.
9. An antibiotic powder is applied to the area and is followed by sterile gauze sponges.
10. A tight bandage is applied to prevent hemorrhage when the tourniquet is removed and some form of impervious covering may be indicated.

PRECAUTIONS

The sawing motion should not be too rapid because heat necrosis of tissues, including bone, may occur, leading to excessive sloughing during the healing period.

Care should be taken to avoid invading the fetlock joint capsule.

POSTOPERATIVE MANAGEMENT

The bandage should be changed 2 to 3 days after surgery. The limb is kept bandaged until the wound has healed. The length of time the wound will need to be bandaged depends on the individual case and to what degree the wound was left open. Some cases of digit amputation may require only 10 to 14 days to heal, whereas others may require several more weeks for the wound to heal by secondary intention.