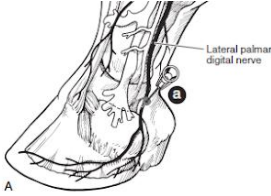
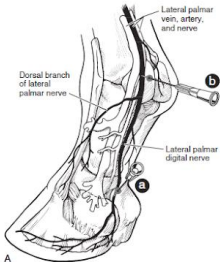
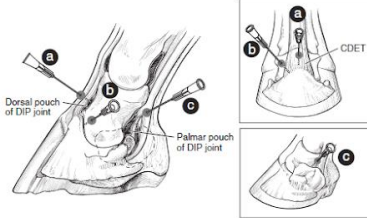
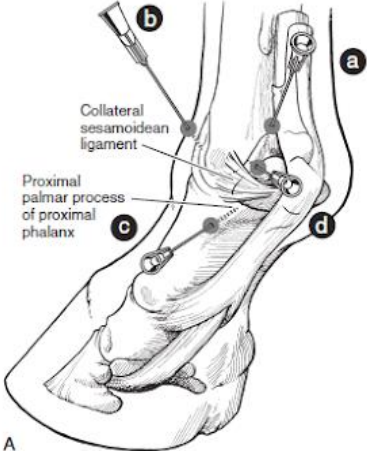
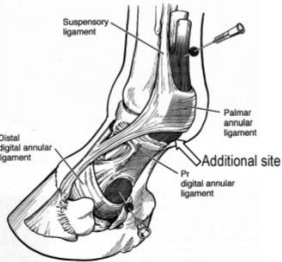


Block	Drug volume per site/ml	Injection site	Needle size	Structures desensitized
Palmar digital nerve block	1-1.5	 <p data-bbox="961 509 1524 743">Needle a Hold up the foot, and palpate for the medial and lateral digital artery and vein. The nerve is the most superficial structure in relation to these. Inject at the level of the collateral cartilage, directing the needle distally.</p>	25G $\frac{5}{8}$ inches	Palmar foot (including the navicular apparatus and distal deep digital flexor tendon), coffin joint, sole
Abaxial sesamoid nerve block	2-2.5	 <p data-bbox="961 1062 1495 1295">Needle b -Distal border of the proximal sesamoid bones to ensure the fetlock does not become desensitized as well -Ensure the needle does not pass below proximal sesamoid bones because this might penetrate the digital tendon sheath</p>	25G $\frac{5}{8}$ inches	Limb distal to the fetlock

Coffin joint block	6	 <p>Dorsal approach is most common (needle a) Lateral approach (b) and palmar approach (c) can be done as well</p>	20G 1.5 inch	<ul style="list-style-type: none"> -Distal interphalangeal synovial membrane, joint capsule, and adjacent soft tissues and subchondral bone by diffusion -The navicular apparatus, distal deep digital flexor tendon and dorsal sole (palmar sole too if >6ml of local anaesthetic agent are used)
Fetlock joint block	6-10	 <p>a-proximal palmar pouch (plantar in hind limb) b- dorsal pouch c-distal palmar pouch d-lateral collateral sesamoidean ligament</p>	20G 1 inch	Synovial membrane, joint capsule, and adjacent soft tissues and subchondral bone by diffusion

<p>Digital flexor tendon sheath block</p>	<p>6-10</p>	 <ol style="list-style-type: none"> 1. Proximal to annular ligament of fetlock 2. Between the proximal and distal digital annular ligament 3. At the base of the proximal sesamoid bone 	<p>20G 1 inch</p>	<p>Synovial membrane and tendon sheath wall; superficial and deep digital flexor tendons and surrounding soft tissues by diffusion</p>
---	-------------	---	-----------------------	--

Images taken from Dyson S, Ross M. Diagnosis and management of lameness in the horse. 2nd ed. St. Louis, Mo.: Elsevier/Saunders; 2011.