

## Septic pedal arthritis

This is a very painful condition and needs prompt radical treatment either with removal of the digit or a 'street nail operation'. Chronic septic arthritis is seen in figure 11.4.7

### 1. 'Street nail operation'

This is an alternative treatment to claw removal for septic arthritis of the distal phalangeal joint. The foot is anaesthetized with a limb block and thoroughly cleaned. A wooden shoe is applied to the unaffected claw. A hole, approximately 1 cm in diameter, is made in the caudal aspect of the sole up through all the underlying tissues into the septic joint between (phalanges) P2 and P3. As much debris and infection as possible is flushed out and the hole is packed with gauze impregnated with antibiotics. The whole foot is bandaged with waterproof tape on the outside. The bandage is changed twice weekly until healing takes place. The animal is given antibiotics and NSAIDs for a minimum of 10 days.

### 2. Digital amputation

Indications, in descending order of frequency are:

- septic arthritis of distal interphalangeal joint
- septic tenosynovitis of deep flexorosteomyelitis of distal sesamoid
- osteomyelitis of distal phalanx, luxation, or fracture of the distal phalanx
- severe digital trauma, e.g. exungulation, loss of much coronary band
- sepsis of coronary band and supracoronary soft tissues.

Advantages

- immediate removal of potentially lethal material (reducing risk of pyemic spread) and to prevent ascending infection of the limb
- relief of pain
- relatively rapid return to thriftiness and production with improved condition and milk yield
- simple surgical technique compared with alternatives

Disadvantages

- potential failure if case selection is poor and infection is present above amputation site
- persisting poor gait in some heavy cows and bulls due to altered stance and strain on remaining digit, especially in difficult terrain. Expected production life is reduced, heavy animals do poorly. Cattle that weigh more than 680kg and have a digit amputated will have a short production life and, so it should not be considered for them.
- lowered market value and culled at lower weights
- few cows with amputated digits are retained for more than eighteen months

Procedure:

It is a rapid and simple procedure and usually provides a wide resection and effective drainage of the affected digit (Figure 11.4-8). The foot is trimmed to remove any overgrown horn. The whole leg below the middle of the metacarpus or metatarsus is clipped and surgically prepared, clipped and washed.

It is best to carry out the surgery under light sedation and with a regional block. A tourniquet is required for both the regional block and the operation. Anesthesia (Figure 19-1). Ring block of the foot may work if specific nerves to the deep structures are blocked (Figure 19-2). The animal is given preoperative antibiotics and NSAIDs. Sedate animal (Ketamine stun, or xylazine 0.1–0.2 mg/kg i.m.) and cast with affected digit uppermost (often lateral hind). Produce suitable analgesia by:

- apply a tourniquet to the midmetacarpal or midmetatarsal region to aid in hemostasis during surgery. Intravenous regional analgesia (IVRA) which is preferred method, or ring block above fetlock
- examine digits to check that infection has not reached level of fetlock joint, and that sepsis is confined to distal part of proximal phalanx and more distal structures
- clip hair from level of fetlock distally to coronet over affected side and over median line, i.e. interdigital space
- remove caked faeces, use stiff brush, run bandage through interdigital space, and give surgical scrub to area

## 2 a. Amputation through distal third of proximal phalanx

Method of amputation obliquely through distal third of proximal phalanx (see Figure 7.7), with preservation of skin flap. Skin flap may be preserved and placed over amputation surface, following removal of digit through distal one third of proximal phalanx. Advantage is cosmetic improvement and faster healing. Although this technique provides a superior cosmetic result and decreases subsequent care of the stump, it may prevent adequate drainage and extension of the infection. The authors therefore recommend this technique for a nonseptic process of the digit (pedal fracture, digit luxation) or distal sepsis without extensive soft tissue infection (pedal osteitis).

Disadvantages include:

- inability to inspect amputation site when dressing is changed
- suture tear out due to post-operative swelling
- risk of skin necrosis
- good case selection is essential (no phlegmon present)

Procedure:

- Skin flap is created initially by an incision between the interdigit skin and around the coronary band horizontally. The interdigital skin is incised to the level of the distal aspect of the proximal phalanx axially, with a 45-degree angle to the proximal digit abaxially. Undermine the skin up until the dew claws. Ensure this flap is large and thick, and is then reflected proximally and retracted by towel clamps. Seen in Figure 15.1 and Figure 15.1A. The skin and subcutaneous tissues are incised to the bone. The skin incision on the axial surface is made fist so as not to obscure the surgical field with blood.
- insert obstetrical or Gigli wire into incision and adjust to a level 1–2 cm above axial aspect of proximal interphalangeal joint, through the first phalanx at the junction of the distal and middle third of P1 (Figure 19-3). Not only is obstetric wire transection efficient, it also contributes to hemostasis. The sawing motion should not be too rapid because heat necrosis of tissues, including bone, may occur, leading to excessive sloughing during the healing period. Care should be taken to avoid invading the fetlock joint capsule.
- with assistant firmly holding digit down towards ground, the saw is directed perpendicular to the long axis of the proximal phalanx to seat the wire in the bone, and then the position of the wire is directed so it is approximately 45° to the long axis of the proximal phalanx so that cut emerges 2–3 cm above abaxial joint level (Figure 15.1B and 15.1C).
- once the digit has been removed, trim off protruding interdigital fat pad and all necrotic tissue, especially that involving the tendons and tendon sheaths, should be dissected sharply from the wound.
- ligate any major vessels e.g. dorsal digital artery lying axially
- examine cut surface meticulously for signs of abscessation and necrosis, peritendinous infection and septic tenosynovitis
- massage distally along deep flexor tendon sheath to check synovia, tissue with simple interrupted purulent synovia should be irrigated out of tendon sheath (catheter, 50 ml syringe and saline), and reconsider need for resection of part of deep flexor tendon
- suture with an absorbable suture (no. 2-0) is used to close subcutaneous tissues; a nonabsorbable suture is used in the skin in a cruciate or horizontal mattress pattern. The corners of these two flaps can then be excised to allow partial closure of the skin incision. Alternatively, a circumferential skin incision can be made in a

similar plane to the wire cut illustrated in Figure 15.1B,C. Forming a skin flap to close the wound would be considered; however, the skin in the area is often necrotic in which it is avoided. Necrotic skin is not conducive to suturing and healing. Complete closure is contraindicated because infection will resolve more rapidly if the skin flap is not completely sutured, to allow better ventral drainage (Figure 15.1D).

- dress wound with oxytetracycline or sulphadimidine powder, apply gauze swab or paraffin-impregnated tulle, and hold in place by pressure bandage and possibly protect by waterproof covering (e.g. duct tape)
- in bandaging avoid pressure necrosis around accessory digits but still apply sufficient pressure as you wrap the surgical area.
- a tight bandage is applied to prevent hemorrhage when the tourniquet is removed (Figure 15.1E),
- inject single prophylactic dose of ceftiofur or long-acting oxytetracycline and, in known risk areas, tetanus antitoxin.

#### Aftercare

- change dressing after two days, when cut surface should be cleaned and checked for residual infection. The whole foot and leg to mid carpus/tarsus is bandaged with soffban and standard bandages.
- foul odour suspicious
- apply new dressing for six days
- surface may then safely be left exposed for granulation and epithelialisation
- rinse wound with water once daily until healing well

Animal should be kept in dry surroundings, either housed (preferably) or outdoors on dry level ground where food and water are easily accessible to avoid overuse of the remaining digit, during the three-week recovery period. The animal is kept under antibiotic and NSAID cover for a minimum of 10 days. The dressing should be changed twice in this period. Remove bandages in 10 to 14 days. If a good healthy bed of granulation tissue has been formed a lightly protective bandage can be applied.

## 2 b. Amputation through coronary band

Involves subsequent removal of extensor process of distal phalanx, proximal part of middle phalanx and the distal sesamoid. This technique is laborious, but was developed to retain potential for growth of a weight-bearing horny wall after surgery. Surgery preferably in recumbent patient.

- groove is made 1 cm distal to horn-skin margin of coronary band
- obstetrical wire saw cut to remove claw, passing through distal interphalangeal joint
- removal of extensor process of distal phalanx, transecting extensor tendon at insertion
- removal of proximal part of middle phalanx and distal sesamoid
- curettage of distal articular cartilage of proximal phalanx
- sharp dissection of any septic or otherwise discoloured soft tissue, or radical curettage

Average survival period following digital amputation in commercial dairy herds ranges from 12–24 months. Exceptions survive for years. Eventual reason for disposal is further digital disease in over half of these cattle. In majority of cases digital amputation has no effect on yield in the lactation subsequent to the one in which amputation is performed.

## 3. Exarticulation at proximal interphalangeal joint or Disarticulation

Advantages are:

- end result of surgery is hollow cavity ideal for pressure packing by bandage or swabs
- avoids exposure of medullary cavity of proximal phalanx which could allegedly become focus of post-operative infection

Disadvantages:

- lengthy procedure
- difficult to locate joint level axially for incision to expose articulation
- liability to break scalpel blades in this awkward site
- preferable use of 'sage knife' (a curved solid two-edged instrument) and a small curette

### **3 a. Disarticulation of the proximal interphalangeal joint**

Involves subsequent removal of extensor process of distal phalanx, middle phalanx, and the distal sesamoid. The indications, anesthesia and preparation are as described above.

A horizontal skin incision is made at the level of the proximal interphalangeal joint, just as above 5-6 cm above the interdigit space, through it, and around the coronary band horizontally. Then cut through adipose tissue and fascia from the palmer/planter aspect of the joint. Intermittently flex the joint to re-establish its location. The incision is continued to the joint capsule to sever the collateral ligament and tendons. As traction is placed on the digit the incision is continued to the axial collateral ligament. Apply firm pressure until the joint capsule between P1 and P2 opens, then follow the curve of the proximal aspect of P3, which tends to follow the coronary band.

Care is taken not to disturb the contralateral digit. The fat pad is excised, and large vessels are ligated, if identified. The advantages of this procedure include the lack of need for assistance in using the obstetrical wire and the quickness of the procedure.

#### **Postoperative Management**

A pressure wrap is placed on the site before releasing the tourniquet. The bandage is changed in approximately 3 days, and the wound is left open to heal by secondary intention unless there is some hemorrhage present when the bandage is changed. In that case the patient is out of a bandage as soon after the procedure as possible.

#### **Complications and Prognosis**

The most common complications of digit amputation are reduction in milk production in dairy cattle for the first 60 days postoperatively, ascending tendonitis, and development of disease on the remaining digit.

In one study, in the authors' opinions, a good recovery from surgery was achieved in 51% of cattle that underwent digit amputation. Poor recovery was deemed in 22% of cattle with the remainder of the cattle having a fair recovery. The mean survival time of cattle recovering from digit amputation ranges from 68 days to 20 months. Heavy cattle (greater than 680 kg) generally have a much poorer prognosis for digit amputation.

### **3 b. Resection of distal interphalangeal joint and distal sesamoid**

Purulent infection of joint and osteomyelitis resulting from spread of solear ulceration, interdigital necrobacillosis and heel abscess in cases nonresponsive to local débridement and several days high dosage of systemic antibiotics, and when digital amputation is either not permitted or desirable. Typically, it is a neglected case of solear ulceration (abscess) with severe distal interphalangeal joint sepsis and osteomyelitis of distal phalanx and distal sesamoid. Technique (see Figure 7.9)

- tourniquet at mid-metatarsal (-carpal) region for intravenous regional analgesia and surgical skin preparation
- carefully probe after removing all visible granulation tissue
- 3-3.5 cm circular incision through horn of sole-heel junction
- remove distal sesamoid bone

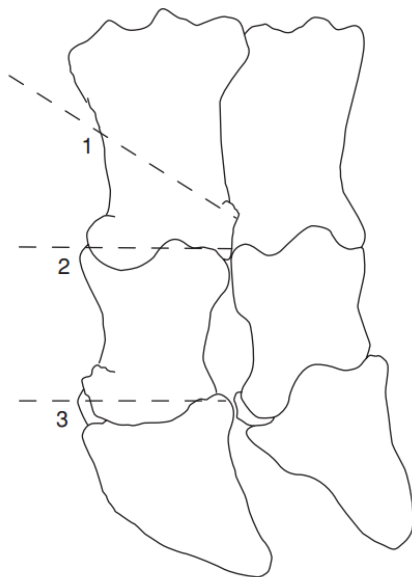


- drill out infected cartilage and subchondral bone of distal interphalangeal joint surfaces
- resect any remains of insertion of deep flexor tendon with 'sage' knife (double-sided, slightly curved solid scalpel)
- if skin and subcutis of coronary border are not involved in sepsis, pack cavity with sterile bandage soaked in povidine-iodine
- if coronet is involved, remove skin (2 cm diameter) surrounding any fistula or incipient abscess with low speed drill, make track 0.8-1.2 cm diameter from sole up through coronary defect
- evaluate usefulness of irrigation tube into cavity and fixed along metatarsus
- insert bandage as above (unless twice daily irrigation is planned) and put block on sound digit
- wire toes to prevent over-extension of operated digit
- high dosage of systemic antibiotics for ten days
- change dressing at two days, then weekly intervals, until granulation tissue has filled defect
- remove block and wire at six to twelve weeks

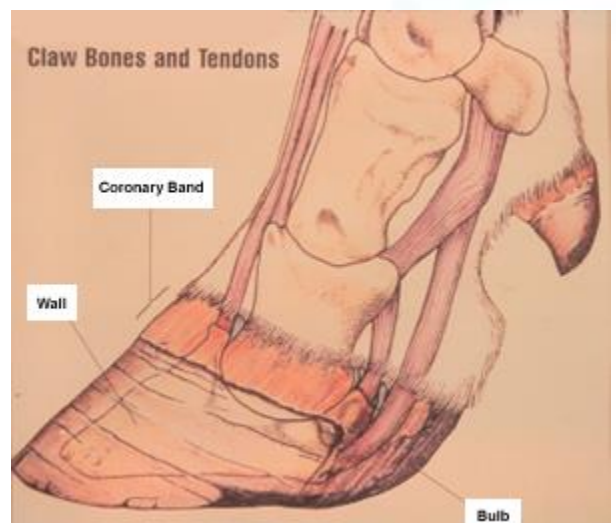
Intensive post-operative care is essential similarly as above. If infection spreads nevertheless, digital amputation may be only alternative to cull (carcass condemnation due to antibiotic residues.)

#### 4. Amputation of the Accessory Digit (Dewclaw)

Amputation of the accessory digit of the hind limb has been described to prevent self-inflicted teat laceration. The technique is simple and easily performed on calves 4 to 8 weeks old. The animal is sedated and kept in lateral recumbency. The area around the accessory digit is prepared aseptically, and a local block is performed around the dewclaw. The dewclaw is pushed proximally to avoid resection of the plantar annular ligament and plantar common digital artery. Sharp dissection with a scalpel is used to remove the dewclaw. Hemostasis is performed, and a bandage with antiseptic ointment is placed on the wound. If the surgery is performed on older cattle, a tourniquet around the distal metatarsus may be used to control haemorrhage.



**Figure 7.7** Sites for digital amputation or disarticulation.  
 1. amputation with oblique cut in distal third of proximal phalanx (open or skin flap technique both possible); 2. exarticulation through proximal interphalangeal joint;  
 3. exarticulation through distal interphalangeal joint.



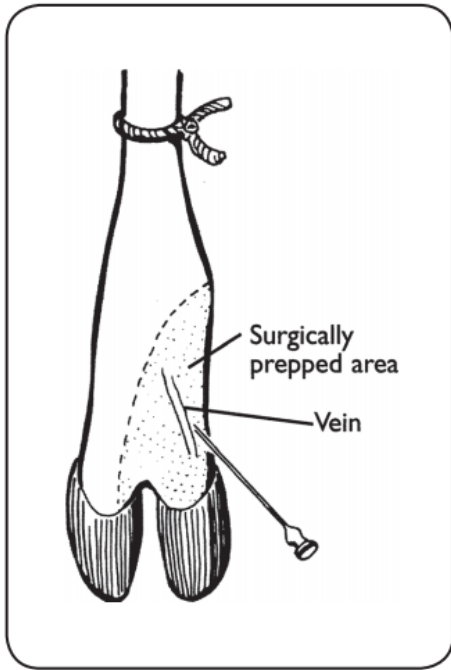


FIGURE 19-1. Local vascular infusion.

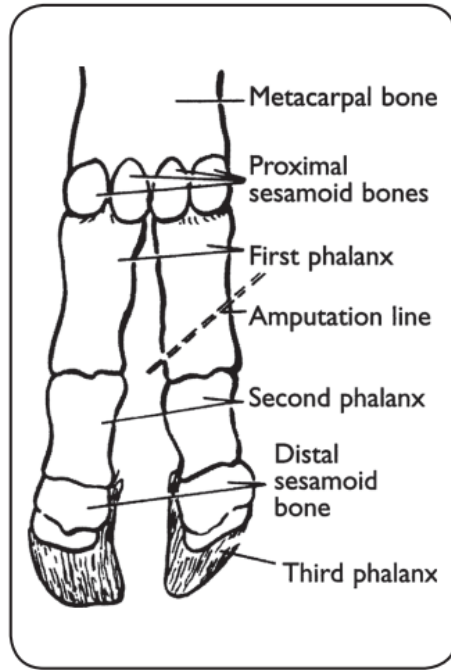


FIGURE 19-2. The volar aspect of the distal forefoot of the ox.

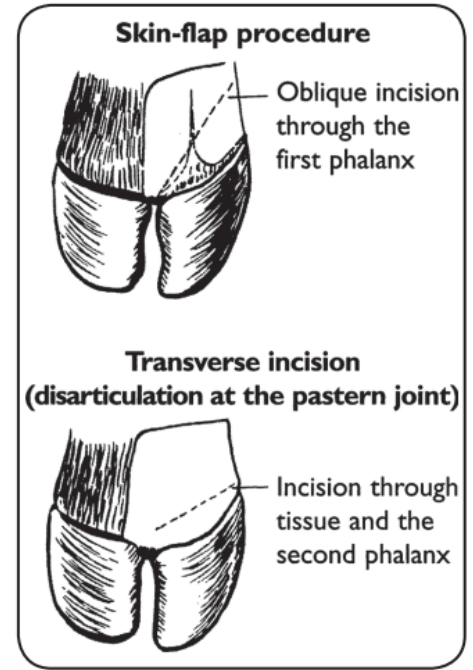


FIGURE 19-3. Two claw amputation methods.

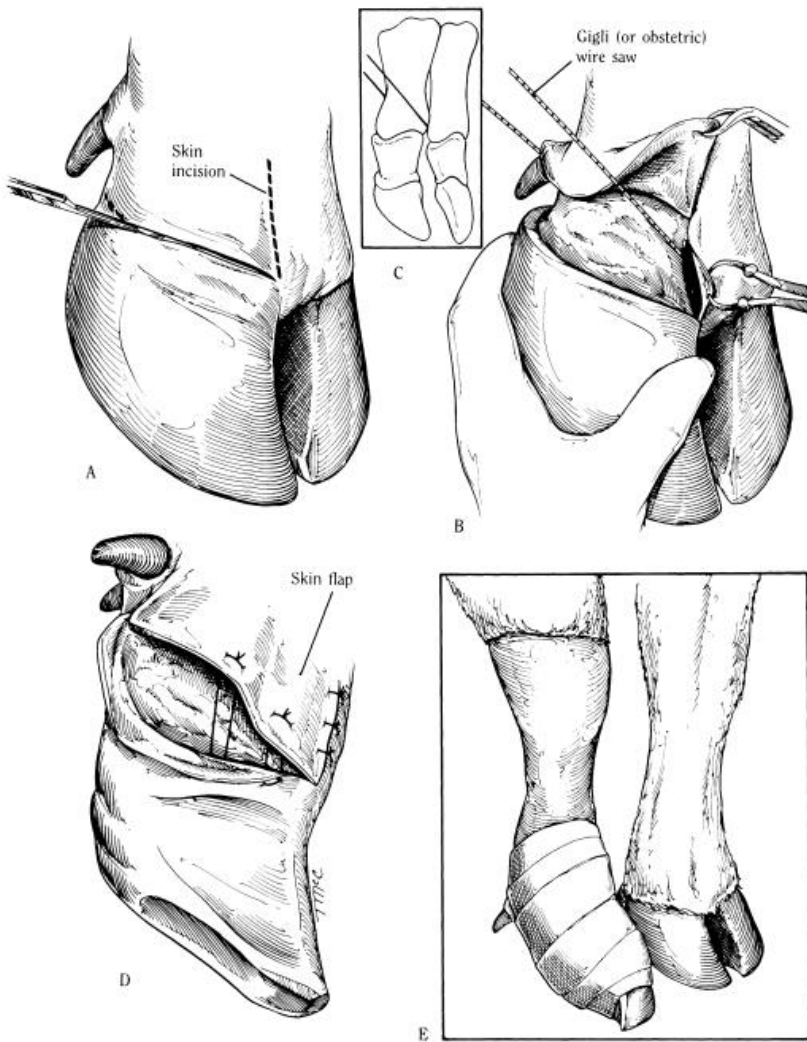
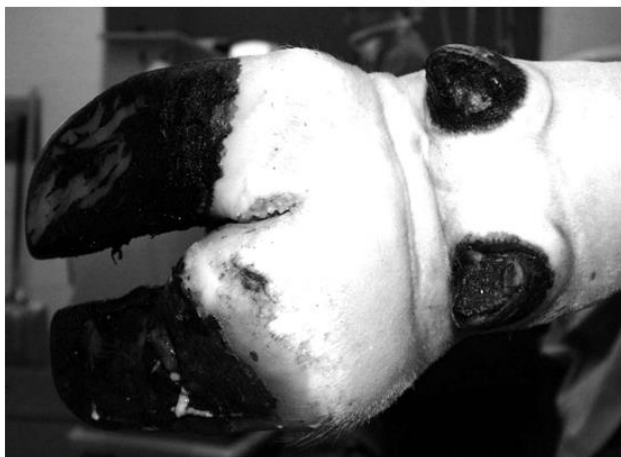
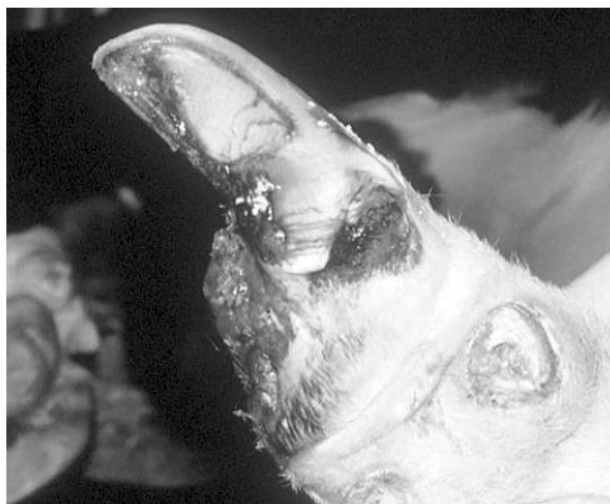
Fig. 15.1. A-E. Digit amputation in cattle.

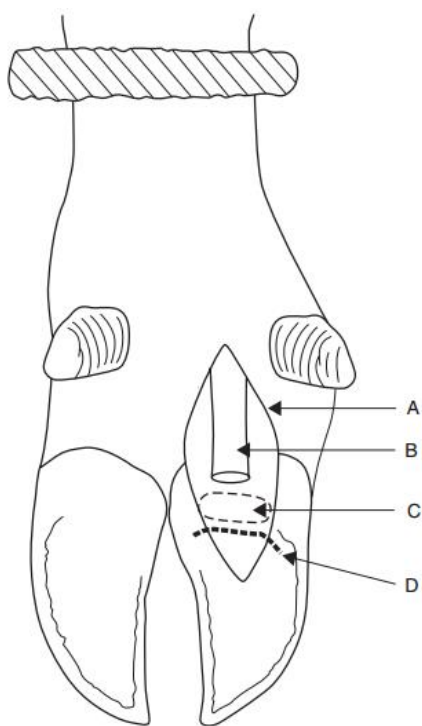


**Figure 11.4-7** Chronic septic arthritis of the medial distal interphalangeal joint in cow. Note fibrous enlargement proximal to the coronary band compared to lateral claw.

(Courtesy of Norm G. Ducharme; Cornell University)



**Figure 11.4-8** Digit amputation, a few days after the surgery was performed.



**Figure 7.9** Resection of distal interphalangeal joint in deep digital sepsis (right hind lateral).

A. plantar skin incision (compare Figure 7.8); B. deep digital flexor tendon, resected distal portion; C. distal sesamoid; D. plantar margin of distal interphalangeal joint.

### **Resection of tendon following digital amputation**

Indication: Septic tenosynovitis complicating deep digital sepsis.

Treatment: Sometimes removal of deep digital tendon is adequate. Other possible procedures are removal of deep and superficial tendons with or without partial or total removal of digital sheath. Precise procedure depends on extent of sepsis at surgical investigation. See Figure 7.12.

#### **1. Resection of digital flexor tendon and their sheaths following digital amputation**

Indication: Extension of infection above level of proposed amputation, without involvement of fetlock joint, is indication for resection of part of deep and superficial flexor tendons and their sheaths (see Figure 7.8).

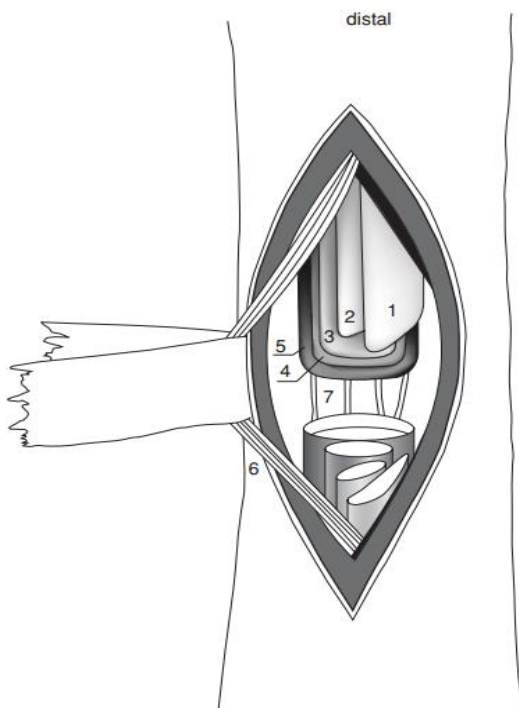


## Technique

- tourniquet at mid-metatarsal (-carpal) region and IVRA , trim back accessory claws and surgical skin preparation to mid-metatarsus (-carpus)
- skin, subcutis and horn of heel bulb are incised over deep flexor tendon from affected distal area (e.g. sole-heel junction), keeping incision axial to accessory digit to point 5 cm proximal to fetlock joint
- open sheath along plantar (volar) aspect
- cut through superficial flexor tendon longitudinally over fetlock (where it encloses deep flexor)
- section deep flexor transversely, just distal to bifurcation (5 cm proximal to fetlock)
- retract tendon from incision and transect distally at insertion into distal phalanx
- check any severe involvement of superficial tendon and, if necessary, resect proximally at same level as deep flexor and at insertion to middle phalanx
- dissect free and resect any infected tendon sheath any exposed, purulent or necrotic sheath and areas of subcutaneous abscessation including curettage as required
- note that minimal amount of tissue should be resected
- insert drain using buhner needle and rubber tubing to allow free flow of tissue fluids out of the body
- dress wound with povidine-iodine-soaked gauze, pack wound, and close proximal half (to below dewclaws) with simple interrupted skin sutures. Keep wound open distally for drainage and removal of gauze packing; bandage firmly. Leave to heal by granulation tissue and apply block to sound claw, and wire toes together
- systemic antibiotics for seven to ten days and change dressing at two, seven and fourteen days, or more frequently if necessary

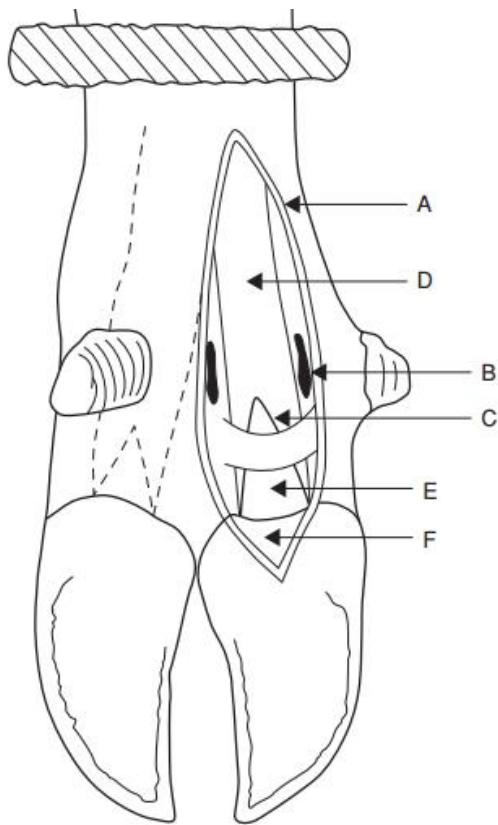
## 2. Alternative method, using approach above fetlock

- incise skin 3 cm proximal to accessory digit immediately over proximal border of flexor digital sheath
- continue this vertical incision down to superficial flexor tendon
- transect both flexor tendons at this point and pull out tendon from amputation site
- remove any septic areas of sheath, which are less well exposed in this method



**Figure 7.12** Tenotomy of superficial and deep flexor tendons and suspensory ligament over left metacarpus (palmar view).  
1. superficial part of superficial flexor; 2. deep part of superficial flexor; 3. deep flexor;  
4. superficial part of suspensory ligament (interosseus muscle); 5. deep part of suspensory ligament; 6. medial vein, artery and nerve; 7. palmar metacarpal veins.  
(From Dirksen, Gründer & Stöber, 2002.)





**Figure 7.8** Surgical anatomy for removal of superficial and deep digital flexor tendons following proximal spread of deep infection. A. incision 12 cm long from proximal to fetlock distally into heel horn; B. sectioned fetlock ligament; C. opened common digital sheath; D. superficial flexor tendon; E. deep digital flexor tendon; F. distal cruciate ligament superficial to distal sesamoid and distal interphalangeal joint.

### Shoeing the cow- Application to blocks to healthy digit

Used to raise pathologic digit above the ground by adding vertical height to the healthy digit with a block. Note, wooden blocks should be sanded after application to prevent the sharp edges from damaging teats, udders and limbs. Surfaces should be prepared before application of resin

- clean off all loose foreign material
- trim any excessive horn from toe, bearing surface, and wall
- apply fat solvent with swabs
- groove bearing surface to increase contact area of resin (grinder very useful and efficient)
- dry hoof with electric hair drier in damp weather
- carefully observe manufacturer's instructions regarding mixing of product

Note that nowadays a wood shoe is usually put on to resin surface (which acts as glue), elevating digit further and saving much resin material, (e.g. Technovit). In using resin to elevate digit, material should be applied as an enveloping moccasin slipper to include part of abaxial and axial wall and toe.

Other uses of resin include the maintenance of toes in close apposition, and for protection of a vertical fissure or sand crack. A specific indication is treatment of fracture of the distal phalanx.

The resin material is extremely hard-wearing but can shatter on sudden impact with stone or brick. After four to six weeks it can be removed by hammer blows, or with electric grinder. Metal and rubber shoes are also available to be nailed onto claw.