

Elastic Band Castration

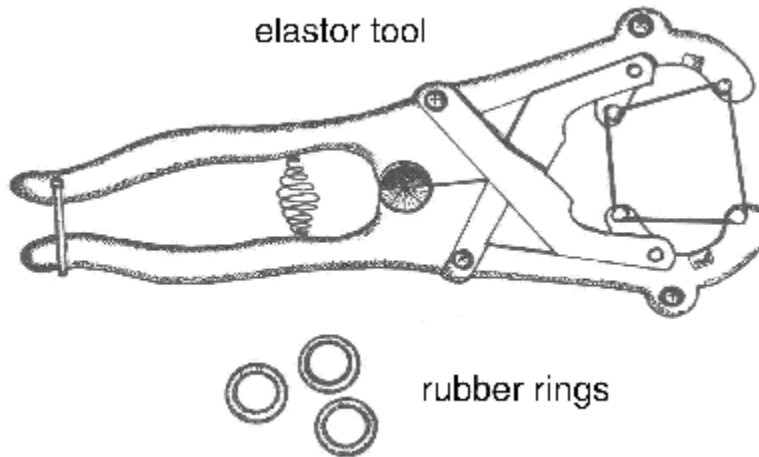


Figure 1. Elastrator tool used to apply rubber rings.

Elastic band castration cuts off blood supply to the testicles. A lack of blood supply kills the testicles. The equipment for banding calves less than three weeks of age is called an elastrator. An elastrator (Figure 1) is the tool used to apply an elastic band to the neck of the scrotum. The elastic band obstructs blood flow to the testicles and the scrotum. In time, the scrotum and testicles fall from the body. The elastrator band is most reliable for calves less than three weeks of age. EZE and Callicrate are tools used to band older, larger calves with latex bands. Vaccination to protect against tetanus and blackleg is recommended. These infections may be more common when older calves are banded. Vaccines must be given weeks in advance of banding. Researchers from Saskatchewan provide strong evidence against using elastic band or surgical castration of mature bulls based on pain response, time to heal and post-castration weight loss. Researchers from Alberta found no advantage in average daily gain with late castration with latex bands vs. surgical castration.

Faulty application of elastic bands results in retention of a testicle and calves with a bull-like appearance (stags). To successfully use elastic bands, the operator must understand the anatomy and restrain the calf properly. Some European countries have banned elastic band castration because officials consider it inhumane.

Technique

1. Use the elastrator technique for calves from birth to three weeks of age.
2. Use elastic rings purchased within the last 12 months to avoid breakage and assure a tight fit. The rings must be strong enough to cut off blood flow in the arteries as well as the veins. If not, the scrotum will swell.
3. Pull both testicles into the scrotum. A muscle attached to each testicle will be pulling against you.
4. Place the rubber band on the elastrator. Hold the elastrator with the prongs facing up. Close the handles to open the band.

5. With the calf standing and both testicles in the scrotum, stretch the ring open and slip the open band up over the scrotum. Release the band just above the top of the testicles (~0.5 cm), not at the base of the scrotum.
6. Check to be sure both testicles are still in the tip of the scrotum and that the ring is placed properly (Figure 2). If not, cut the ring with scissors and start again.
7. Remove the elastrator from under the band.
8. EZE or Callicrate bands are applied in a similar location. See the manufacturer's literature for detailed instructions.

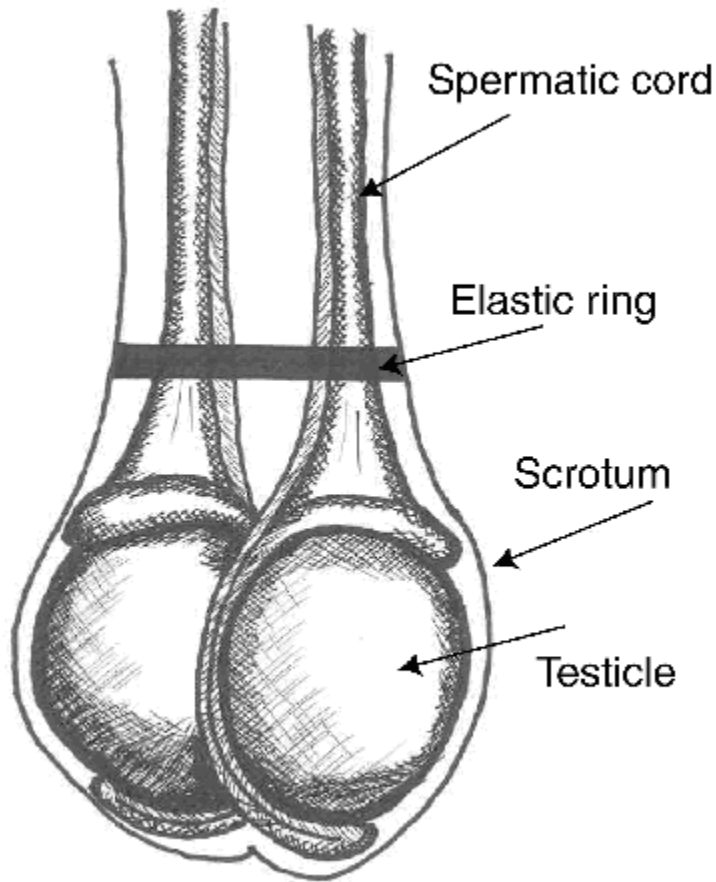


Figure 2. Elastic band at top of testicles.

Pain:

- local anaesthesia virtually eliminates the acute pain caused by rubber-ring or latex-band castration
- acute pain caused by banding is greater than that caused by
- Burdizzo clamps

Advantages and Disadvantages:

- bloodless, easy to perform
- large lesions may form above the band site and persist for long times, making latex bands inappropriate for yearling cattle
- wounds heal more slowly than those from surgical castration
- newest versions of banders for older calves adjust the latex bands to correct tension
- potential for missed testicles
- band may break or band may not disrupt all circulation to the testicles
- preferred for castrating at a wet, muddy feedlot
- infections, including tetanus and blackleg, may warrant vaccination prior to banding
- public concern about pain and animal welfare associated with banding older calves
- lower weight gains following latex-band castration compared to surgical castration
- EZE and Callicrate methods without anaesthesia for older bulls deemed inhumane and unethical