
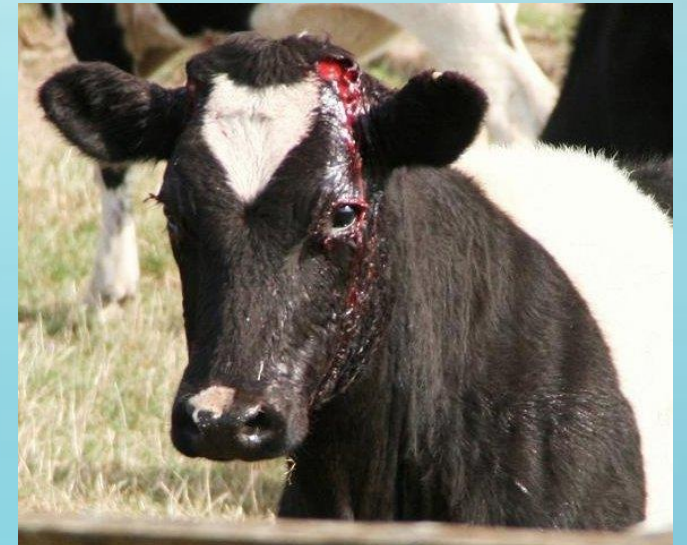
**POTENTIAL**  
**COMPLICATIONS**  
**ASSOCIATED WITH**  
**DEHORNING AND**  
**DISBUDDING**

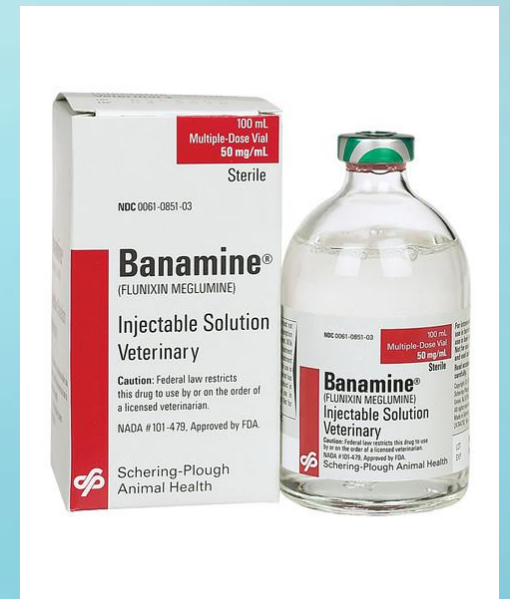# Haemorrhage:

- The risk of haemorrhage is greatly increased in older calves/goats.
- It is important to dehorn completely and ensure there is a copper-coloured ring all the way around the base of the horn when using the hot iron dehorner.
- Observe animals closely for one hour following procedure.



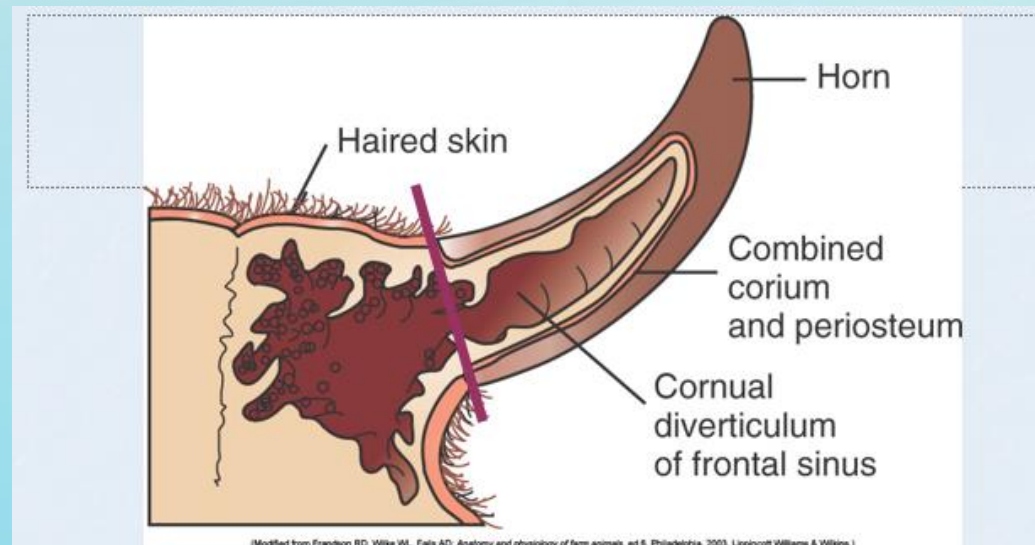
# Pain:

- Animals should be monitored during and after the procedure for signs of unnecessary pain, such as vocalization, reluctance to move, and failure to nurse.
- Our patients were treated with a systemic analgesic ,Flunixin Meglumine before the procedure.
- Severe pain warrants the attention of the veterinarian.



# Horn regrowth:

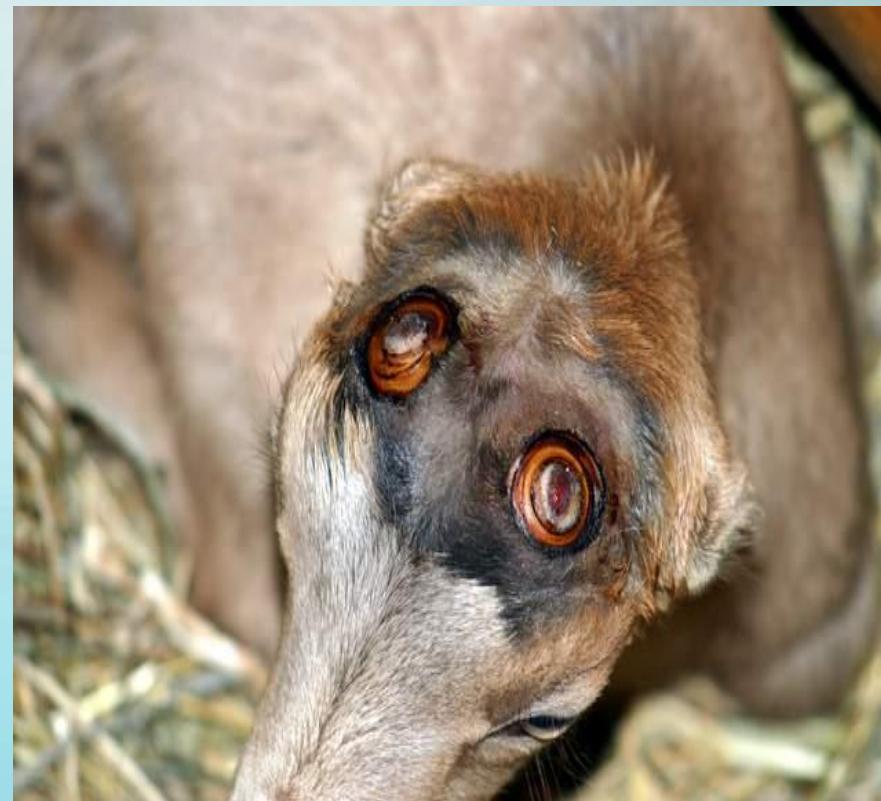- Inadequate removal of the corium (horn-producing cells) will result in the regrowth that leads to scurs (common in intact male goats)
- Depending on the extent of the regrowth, the dehorning procedure may need to be repeated.



- Longitudinal cross-section of a horn, showing extension of the frontal sinus of the skull into the horn. Dehorning, which is performed at the base of the horn, exposes the sinus

# Tips to prevent or manage horn regrowth:

- When disbudding an animal with a hot-iron, be sure to treat a ½-inch (approximately 1-cm) wide ring of skin around the horn bud to prevent regrowth.
- In an older animal, remove a ½-inch (approximately 1-cm) ring of skin around the horn base along with the horn itself before using any dehorning equipment.
- Monitor animals after to make sure there is no regrowth.
- If horn regrowth does appear, repeat cauterization again as soon as possible. If you're unsure how to deal with the regrowth, consult your veterinarian.



# Flystrike:

- Fly strike is a problem when animals have an open wound but if dehorning is carried out in a hygienic manner, wounds heal up quickly. Do not apply an insecticide straight on the wound, but rather around the wound. Wound disinfectants can be applied to the wound to reduce infection risks.



This treatment was applied around the infected areas for the next 3 days post-op.

<https://ar.zoetis.com/products/bovinos/matabichera-fd.aspx>



# Infection/ Sinusitis:

- Animals should be monitored for signs of infection in the days following procedure, such as redness, swelling, and discharge.
- Sinusitis is a particular risk in older animals, due to the fact that as the horn grows, the frontal sinus grows into the centre of the horn, and thus removal of the horn creates a defect in the skull that extends into the sinus, and thus an opportunity for infection.

**Figure 1:** Purulent discharge from the frontal sinus dehorn in an adult cow





# Tips to prevent infection/sinusitis:

- Animals were administered a prophylactic treatment of Penicillin.
- <http://www.d1017149-6547.belgacomhosting.be/kelalab/index.php5?page=24&lang=3&animal=9&view=detail&id=32> →
- If sinusitis is discovered the same dose of Penicillin administered prior to procedure should be repeated 72 hrs after.
- There was no indications of infections from both patients, Peppy and Timothy.
- Tetravet spray was applied directly on the affected areas for the next 3 days post-op.
- Avoid the use of elevated feeders immediately after the procedure to prevent entry of debris into the wound
- Minimize environment exposure, as dust and rain may increase the risk of sinusitis.



<http://www.takamuljo.com/ItemDetails.aspx?ItemID=31&ProductName>



# Diseases transmitted:

- Diseases can be spread from animal to animal when using equipment contaminated with blood.
  - Enzootic bovine leucosis virus and the wart virus (cows)
  - Caprine arthritis encephalitis virus (goats)
- Equipment should be disinfected between usage in herd.

## Technique

1. Rinse blood off with cold water after each animal is dehorned.
2. Place the equipment into an antiseptic after the animal is dehorned.
3. Change the antiseptic solution frequently to maintain its potency.
4. Prepare a disinfectant solution by adding four ounces creosol to one gallon of water.
5. Store the equipment only after cleaning and disinfecting.

## Potential decreased weight gain following dehorning of older animals due to pain and stress:

- Animals should be dehorned as young as possible to minimize stress.
- Use of local and systemic analgesics is recommended.

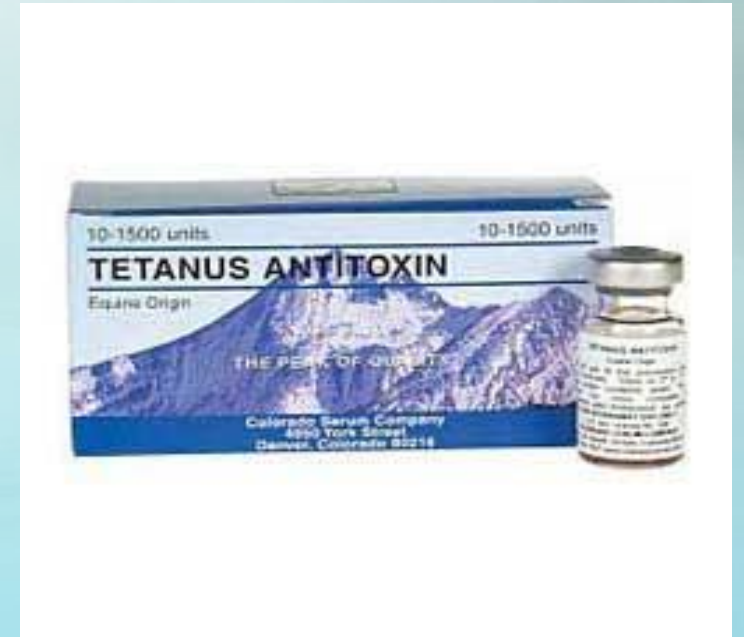# Tetanus:

- Tetanus usually results from contamination of deep puncture wounds. Castration and dehorning wounds are another risk, as are wounds from calving trauma.
- *Clostridium tetani* organisms remain at the site of entry, multiply, and produce a toxin that affects the nervous system, causing stimulation and contraction of the skeletal muscles. The affected animal will appear stiff, the tail is held out, the head
- The use of tetanus antitoxin should be considered, and animals should be vaccinated for tetanus.

# Tetanus in goats:

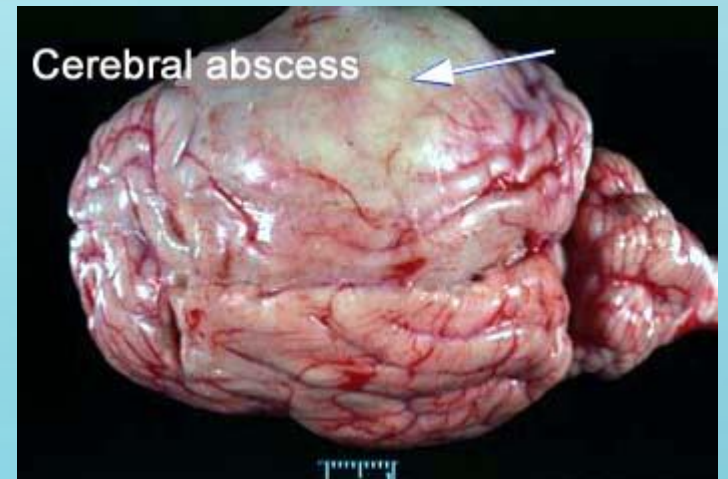
- [https://www.youtube.com/watch?v=ENIEey\\_4I90](https://www.youtube.com/watch?v=ENIEey_4I90)
- <https://www.youtube.com/watch?v=6YuAuJJK2kg>
- All adult goats should be vaccinated with a tetanus toxoid prior to performing a dehorning procedure. A booster of this vaccine should be given at the time of dehorning.
- Tetanus toxoid vaccines should also be considered in kids when they are disbudded at older ages.
- If the vaccination status of the animal is not known, then tetanus antitoxin should be administered at the time of disbudding/dehorning (250 IU should be given to kids and 500 IU should be given to adults).

- [http://www.colorado-serum.com/csc/tet\\_antitoxin.html](http://www.colorado-serum.com/csc/tet_antitoxin.html)



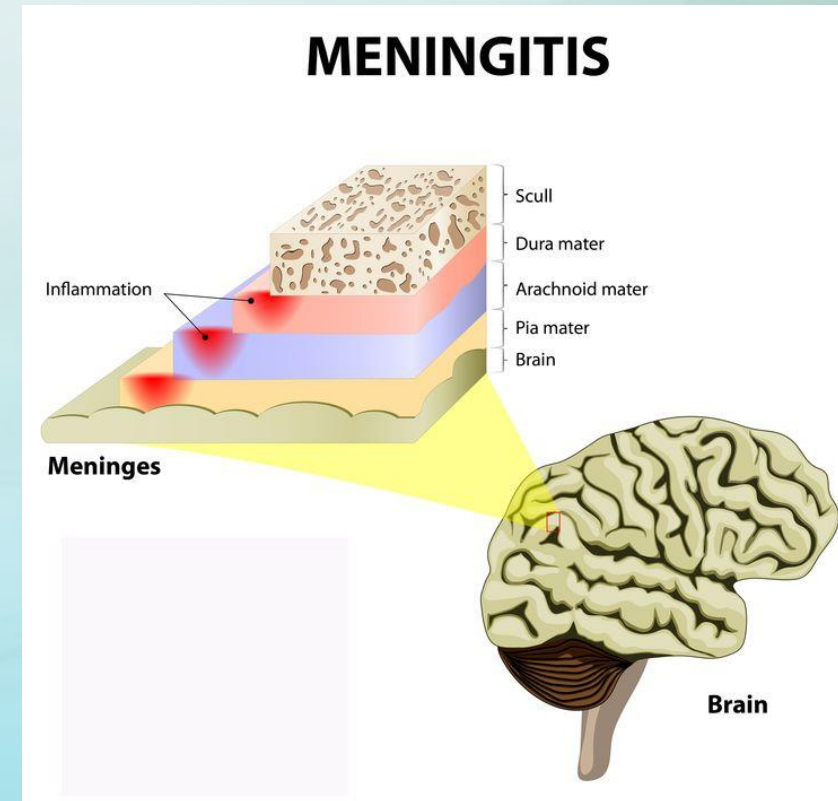
# Brain abscess:

- Heat cautery may destroy bone overlying the brain thereby permitting entrance of bacteria.
- Too low a saw cut on the mature goat can also penetrate to the brain.
- The animal that develops neurological signs referable to the cerebral hemispheres several weeks after dehorning may have a brain abscess.



# Heat meningitis:

- Prolonged application of a hot iron to a kid's horn buds can damage the underlying bone, meninges or brain.
- The frontal bone is thin and the frontal sinus is not yet developed at the time ideal for disbudding.
- Coagulative necrosis of meningeal vessels can result in thrombosis and infarction of the underlying cerebrum.
- Problems are most apt to occur when a dehorner is not hot enough to rapidly sear the skin.
- The longer the iron must be applied, the more heat will penetrate to deeper layers





# Clinical signs:

- History of animal
- Depressed mental state
- Cortical blindness
- Circling/leaning
- Head pressing
- Opisthotonus
- Vocalization
- Seizures
- Bizarre behavior



- Allowing the head to cool before finishing disbudding is advisable if the iron is not very hot.
- Young kids – allow to nurse post-dehorning and they never act painful.
- Older kids, adult animals, or if complications:
  - NSAID's (Banamine 0.5 to 1.1 mg/kg SID or BID,
  - Meloxicam 1mg/kg SID, Aspirin 80 to 320 grains BID depending on size of goat)
  - Narcotics – (bupomorphine, butorphanol) not generally necessary

THE END

