

GHENT UNIVERSITY

FACULTY OF VETERINARY MEDICINE

Academic year 2010-2011

**THE OCCURRENCE OF VAGINAL
PROLAPSE
IN SHEEP AND CATTLE**

By

Margaux KUIJLAARS

GHENT UNIVERSITY

FACULTY OF VETERINARY MEDICINE

Academic year 2010-2011

**THE OCCURANCE OF VAGINAL
PROLAPSE
IN SHEEP AND CATTLE**

By

Margaux KUIJLAARS

Supervisor: Prof. Dr. Aart De Kruif

Case Study

Tabel of Content

Summary	1
1. Introduction	2
2. The First Case Report	3
2.1 The Patient	3
2.2 The Initial Course of Action	4
2.3 The Fetus.....	5
2.4 Placing of the Buhner Suture	5
2.5 Awaiting Parturition.....	6
2.6 Partus and Postpartum.....	8
3. The Second Case Report	11
3.1 The Patient	11
3.2 The Partus and Postpartum.....	11
3.3 Amputation of the Vaginal Prolapse	13
4. A Case of Mismanagement	14
5. Literature Review/Discussion	17
5.1 Anatomy and Fixation of the Vagina	17
5.1.1 The Vagina	17
5.1.2 The Ligaments.....	17
5.1.3 Muscles and Fascia.....	18
5.2 Causes of Vaginal Prolapse	19
5.2.1 Hormone Profile's and Vaginal Prolapse.....	19
5.2.2 Vaginal Prolapse a Hereditary Trait	22
5.2.3 Collagen metabolism and Vaginal Prolapse.....	23
5.2.4 Vaginal Prolapse and Nutrition.....	24
5.3 Assessment of the Vaginal Prolapse.....	27
5.4 Replacement of the Vaginal prolapse	29
5.4.1 Acute Vaginal Prolapse	30
5.4.1.1 Epidural Anesthesia.....	30
5.4.1.2 Retention Sutures.....	31
5.4.2 Chronic Vaginal Prolapse.....	33
6. Conclusion	36
References	37

The author gives permission for this study to be consulted for personal use. Every other use is subject to the limitations of copyright, particularly concerning the obligations to specifically mention the source when citing results of this thesis. The copyright concerning the data mentioned in this literature analyses rests with the supervisor. The original copyright of individually cited studies and possible associated documentation, such as tables and figures, remains protected. The author and the supervisor are not to be held responsible for possible treatments and dosages cited and described in this study.

Summary

Eversion and prolapse of the vagina is a problem most frequently found affecting both sheep and cattle. The following paper, will examine three different cases of vaginal prolapse: two concerning sheep and one concerning a cow. Case one is that of a cow treated for her vaginal prolapse at the department of obstetrics and reproduction at the faculty of veterinary medicine in Ghent. Case two is about a sheep that was treated by a local veterinarian after her vaginal prolapse became necrotic. The third and final case illustrates the violation of animal welfare in a sheep suffering from a vaginal prolapse. Hereafter, a discussion and literature review follows in which the vaginal prolapse as a concept is more thoroughly examined. First of all the causes of vaginal prolapse will be explored. Then a more practical section on the assessment and treatment of both acute and chronicle vaginal prolapse rounds of this paper.

1. Introduction

Eversion and prolapse of the vagina is a problem frequently found affecting both cattle and sheep. Most commonly the problem presents itself in mature females during their last trimester of pregnancy. Although vaginal prolapse occurs mainly in pregnant cattle and sheep, the condition is also seen in non pregnant ewes and heifers (Kahn, 2005). In addition, post partum vaginal prolapse has also been documented (Hosie, 1989).

The hormonal changes that occur during this last trimester of pregnancy, especially the increase of estrogen and the production of relaxin, cause a relaxation of the pelvic ligaments and surrounding soft tissue structures (Wolfe, 2009). The combination of this tissue relaxation with the increased intra-abdominal pressure caused by the pregnant uterus, is considered the number one predispositioning factor for vaginal prolapse (Kahn 2005). Other factors capable of increasing this intra-abdominal pressure such as intra-abdominal fat accumulation, rumen distention, large fetuses, more than one fetus and the occasionally hilly terrains also make their contribution to the occurrence of vaginal prolapses' (Drost, 2007). A various number of dietary factors such as hypocalcemia and the grazing on pastures with an abundance of clover have also been linked to the disorder (Miesner and Anderson, 2008). In addition to this it is assumed that the occurrence of vaginal prolapse has a genetic foundation in both cattle (Brahman, Brahman crossbreds and Herford) and sheep (Kerry Hill, Romney Marsh) (Kahn, 2005).

A vaginal prolapse begins just cranially of the vestibulovaginal junction as a folding of the vaginal floor. The discomfort caused by this eversion in addition to the resulting irritation and swelling of the vaginal mucosa, is the start of a vicious cycle characterized by increased straining and the formation of a more extensive prolapse (Kahn 2005). In extreme cases the entire vagina may prolapse with the cervix displaying itself at the most caudal part of the prolapse.

A vaginal prolapse may not directly be considered an emergency but, if not treated, the vagina becomes swollen, edematous and congested and is therefore very susceptible to injury. With the vaginal mucosa compromised a spontaneous rupture of the vaginal wall is not unheard of (Hosie, 1989). An addition complication that may require urgent attention, is the containment of the bladder within the prolapsed vagina. Not only does the bladder potentially hinder repositioning of the prolapse, it is quite likely that a consequential obstruction of the urethra results in the distention of the bladder and in a worst case scenario a bladder rupture. Other structures such as the intestines and the uterus may also be contained in the vaginal prolapse. A spontaneous rupture of the vaginal wall with herniation of the intestines, bladder or uterus, therefore also belongs on the list of complications to be associated with vaginal prolapse (Veeraiah and Srinivas, 2010).

In this thesis two case reports will be fully examined. The first case report concerns a Belgian Blue cow treated at the Department of Obstetrics and reproduction for a vaginal prolapse. The second case study is that of a Zwartbles sheep, treated for a vaginal prolapse by a local veterinarian. Following this a case of maltreatment of vaginal prolapse in a sheep will be briefly discussed. Hereafter a literary analysis follows, assessing what is known today with respect to vaginal prolapse.

2. The First Case Report

2.1 The Patient

On the first of July 2010 a five year old Belgian Blue cow was brought to the Department of Obstetrics and reproduction, Faculty of Veterinary Medicine, Ghent University. In addition to the many horses that are annually brought to this department, Belgian Blue heifers and cows constitute a large part of the department's patient database.

The Belgian White Blue breed is a double muscled breed. This double muscled phenotype, is caused by a genetic mutation in the gene for myostatin, a negative regulator of muscle growth (Thomas et al., 2000). More specifically Belgian Blue cattle are homozygous for an 11-bp deletion in the gene coding region that is not detected in cDNA of any normally muscled animals examined. This deletion results in a unique frame-shift mutation in the part of the myostatin gene most highly conserved in our more traditionally muscled animals (Kambadur et al., 1997). Piedmontese cattle also displays the double muscled phenotype and upon examination of their genotype, alterations were found in the same gene coding region (Kambadur et al., 1997). The result of this mutation is a muscular hyperplasia. The expression of the myostatin gene is present from early fetal development onwards in both phenotypically normal and phenotypically double muscled animals (Thomas et al., 2000).

Consequently the instigated muscular hyperplasia leads to calves with twice the muscular volume and in the case of the Belgian Blue an entire breed of cattle no longer capable of calving naturally. Hence the reason why Belgian Blue heifers and cows constitute a large part of the department's patient database. The five year old Belgian Blue cow that concerns us in this particular case was no exception, she had already undergone two cesarean sections and was due to calve again on the 11th of July 2010 undoubtedly by means of yet another cesarean section.

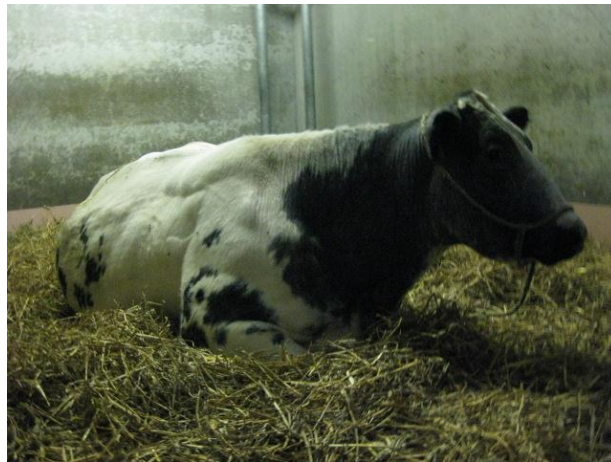

Figure 1: The Patient

What set this patient aside from the other Belgian Blue's was the pink volleyball shaped tissue mass protruding from her vulva. This was clearly a case of vaginal prolapse.

2.2 The Initial Course of Action

On the day of arrival, after a short clinical examination, the decision was made to undertake as little action as possible. After taking the necessary hygienic measures a small epidural using 2cc's of procaine (4%) was placed between the first and the second coccygeal vertebrate and the prolapse was gently massaged back into the pelvic cavity. The choice to undertake such limited actions was based upon the following: the patient was not straining vigorously and she was due to calve shortly. For the time being the situation appeared stable: when the cow laid down the vagina had a tendency to prolapse but when encouraging the cow to stand up the prolapse would spontaneously resolve itself. Twenty-four hours later the situation however worsened; the patient began straining more forcefully and the prolapsed vagina no longer spontaneously resolved when the cow stood up. On the 2nd of July at 20:00 a new epidural was given and the vagina was repositioned as described above.

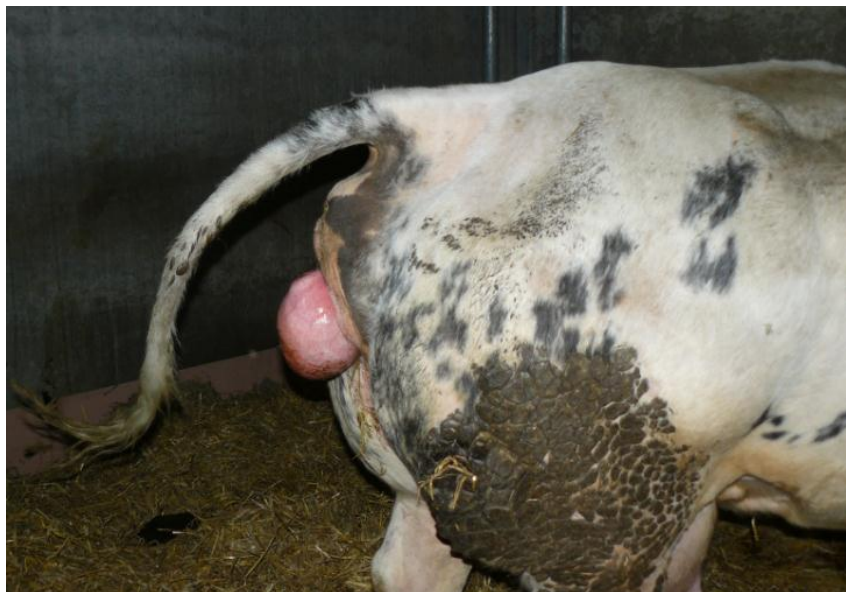

Figure 2: The vaginal prolapse

Over the course of two weeks the problem did not diminish. After three days of struggle the cow was placed on a wedge in order to elevate her hindquarter. The hope was that positioning the cow as such would better facilitate for the repositioned vagina to stay in the pelvic cavity. In addition to this, the anesthetic used to bring about the epidural anesthesia was switched from procaine to marcaine (bupivacaine), a longer acting anesthetic. Because the results obtained after administering epidurals with procaine had been insufficient it was hoped that the use of a longer acting anesthetic would prove superior. The result was unfortunately not as good as desired.

A next, and only slightly more invasive measure, was going to be the placement of a Buhner suture. A Buhner suture is a continuous circular suture that can be pulled together to invert or close an opening. In this case it would be required to place the suture deeply in vulvar tissue in order to mimic the effect of the constrictor vestibulae muscle (Pitmann, 2010). The problem with this patient was that her quickly approaching due date made it attractive to wait with such measures, as a Buhner suture must be removed prior to calving to prevent extensive laceration (Kahn, 2005).

2.3 The Fetus

On 16/7/2010, five days after the expected due date questions began to arise concerning the age and livelihood of the fetus. Whilst an early stage pregnancy is most commonly confirmed via a rectal exam, possible with the aid of a transrectal ultrasound, both techniques pose limitations when it comes to the diagnosis of mid and late term pregnancies. Between day 90 and 120 of pregnancy the gravid horn sinks from within the pelvic cavity to below the cranial pelvic rim . By the 6th month of pregnancy the gravid horn has sunken deep enough to fill the space between the right flank and the abdominal floor (Hunnam et al., 2009). As a result of the shifting of the gravid uterus horn most structures required for a positive pregnancy diagnose are beyond the reach of a transrectal probe (Hunnam et al., 2009). Fortunately the rectal exam of a cow potentially already three days overdue is more likely to confirm a pregnancy and this through the palpation of both parts of the fetus and the placentomes, in addition to the chance of detecting fremitus in both the ipsilateral and contralateral middle uterine artery (Intervet International, 2011).

Strangely enough the records kept on this patient do not document that a rectal exam was carried out at this stage. Instead, it appears that a transabdominal echo was made to evaluate the situation. On the transabdominal echo the calf's head and extremities where visualized, but neither the ribcage nor the heartbeat where seen. This information really does not lead us very far. Without seeing the heartbeat one cannot confirm that the fetus is still alive and seeing bone structures only confirms that the cow has been carrying for over two months (Purohit, 2010).

Although maybe not as accurate at this stage of the pregnancy, it would have been possible to use the images obtained via the echo, in a more productive way. By taking certain specific measurements, such as the crown-rump length and the crown-nose length, one could have calculate an approximate fetal age. This is simple done by means of a set of standard regression formulas created to utilize specific measurements to calculate the fetal age (Rexroad et al., 1974 and Riding et al., 2007).

With the many options available to better estimate the potential due date it leaves me guessing why there was not more done or documented with respect to this dilemma. What the patient's records do make clear is that the results of the transabdominal echo lead to the general impression that this cow was not going to be calving any time shortly. With this in mind and due to the failure of alternative methods, it was finally decided to place a Buhner suture.

2.4 Placing of the Buhner Suture

In order to place the Buhner suture, the patient first received an epidural using 12cc of procaine. After washing the involved tissues and repositioning the vaginal prolapse as described above, a Buhner needle was inserted through the vulva. The needle entered the vulva through the fine-haired skin below and slightly lateral to the ventral commissure of the vulva and reappeared at an equal distance above the dorsal vulvar commissure. It is important that the Buhner suture is placed sufficiently deep into the perivaginal tissue in order to give strength to the suture. After placing the needle, a piece of umbilical tape was placed through the loop eye of the needle and the needle was removed via the dorsal opening, hereby threading the umbilical tape through the full length of the right vulvar lip. The same course of action was then repeated, this time inserting the needle a little bit to the left of where

the umbilical tape appeared above the dorsal vulvar commissure and ending underneath the ventral vulvar commissure. The result of the described procedure should be a circular suture that is best tightened to allow no more than three fingers to pass through the vulva opening. A bowtie is made to facilitate an easy opening of the suture, making it unnecessary to redo the entire suture every time access to the vagina is required, for instance when needing to perform a vaginal exam. To combat the possibility of wound infections the contents of an udder tube of Nafpenzal was injected into the four suture openings.

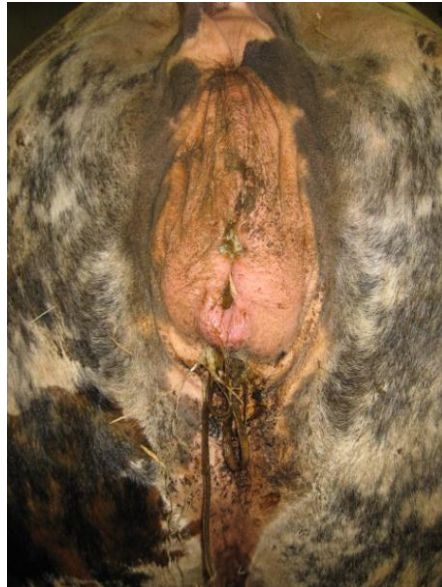

Figure 3: The Buhner suture

2.5 Awaiting Parturition

With the prolapse problem temporarily under control the most important task remaining was to supervise the cow carefully for signs of an approaching parturition. The daily registration of the patient's body temperature made an important contribution towards carrying out this task. In fact it is the standard procedure at this faculty to daily record the rectal temperature of all cows and heifers brought in to calve. It has been reported that the body temperature 28 hours before calving can drop as much as 1°C (Weber, 1910). Research has linked this rather consistent drop in temperature prior to calving to the hormonal alternations that take place at this time. Speculations have even been made that the precalving decrease in body temperature could increase fetal temperature hereby inducing an important compensatory mechanism for the body temperature loss that occurs after delivery in newborn calves (Lammoglia et al., 1997).

In cows the pelvic ligaments, especially the sacro-sciatic ligaments, become progressively relaxed as parturition approaches (Purohit, 2010). This sign of approaching parturition is clearly palpable and also somewhat visible because of the tail base appearing more raised. As with the drop in body temperature before calving, the relevance of the relaxation of the pelvic ligaments in estimating the proximity of partus is not to be underestimated.

Further external changes, in addition to certain behavioral changes, all contribute to forming a general notion of the time of parturition but they do not permit an accurate prediction. The udder for instance becomes enlarged and possible edematous prior to parturition. In heifers this enlargement of the

udder may already be noticed midway the pregnancy, whilst in pluriparous cows it may only become apparent two to four weeks before parturition (Purohit, 2010). The vulva is also susceptible to swelling before parturition, but the timing of this event varies greatly amongst individuals. This swelling of the vulva may be paired with the formation of edema. Especially in heifers this edema can become so extreme that it extends from the vulva down to the udder sometimes even reaching the umbilical region. In such cases the edema is considered pathological and one must differentiate it from a potential hernia or hematoma (de Kruif and van Soom, 2009). Vulvar discharge is another sign of approaching parturition. Due to the liquefaction of the cervical seal and mucus production in the vagina, vaginal discharge may be seen one or two days before parturition. Unfortunately in some cases this discharge may already become apparent as early as two weeks before parturition. If the discharge is mixed with blood it is an indication of the fact that the accessory placentomes close to the cervical opening are detaching and parturition is close by (de Kruif and van Soom, 2009). Several times in the course of the months that followed it was believed that the cow was going into labor. Naturally these false alarms were fueled by the presence of a Buhner suture and the lack of knowledge concerning the cow's gestation time. On the 3rd of August the cow was found in lateral decubitus exhibiting clear signs of discomfort. Due to the passing of time the bowtie initially holding the two ends of umbilical tape together had transformed itself into a knot and it ended up being necessary to remove the entire suture before vaginal exploration was possible. The vaginal exam taught us that the cervix was not yet passable by more than one finger and the cow, much to her displeasure, received a new Buhner suture without first being given an epidural. The new Buhner suture despite several other reports of false labor, was eventually in place for several months and this was not without consequence.

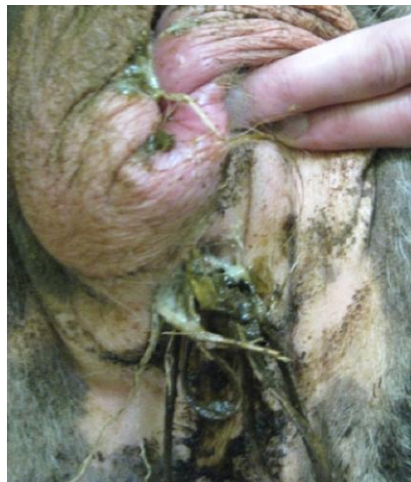

Figure 4: Infection of the vulvar tissue

The vulvar tissue had become infected and the frequent observation of small amounts of pus being discharged from the vagina made it plausible that the cow was also suffering from a mild vaginitis. In addition to this, leaving the Buhner suture in place for such a long period of time, had led to the

formation of scar tissue around the umbilical tape. Initially this may be seen as an advantage as the scar tissue ring will continue to combat the vaginal prolapse long after the removal of the Buhner suture (Pittman, 2010). However a vulva with a scar tissue ring will not be able to stretch enough to allow for a smooth natural calving, fortunately for this patient that was of little concern.

In an attempt to combat the infection the wounds were washed on occasion with chlorhexidine and the content of a nafpenzal uddertube was once again injected into the four penetration points of the Buhner needle. Despite these measures, it was reported that the vulvar tissue had become necrotic to the extent that the Buhner suture tore out.

Luckily this incident occurred around the time that it became clear to everybody that the patient was finally going to calve very shortly. In preparation for this long awaited moment the cow had already been removed from her wedge in the hope that this would allow for the calve to gain better access to the birth canal. In fact this was done a few weeks earlier on the 12th of October. On this day a rectal exam had been carried out that finally gave some concrete information, the calf was most likely alive as fremitus was felt both contralaterally and ipsilaterally and he/she was lying in an anterior presentation with both front legs and head palpable.

2.6 Partus and Postpartum

On the 26th of October, almost a full four months after her calculated due date the caesarean section was performed. Unlike speculated, not a single complication occurred during the operation and a healthy bull calf of 52 kilos was delivered.



Figure 5: The long awaited calf and his mother.

After the caesarean section it is the common procedure that both the calve and the cow remain at the clinic for another two to three days. In this time the proper after care is given. This aftercare includes: the insurance that the calf receives sufficient colostrum and learns to drink independently, the administration of antibiotics to both cow and calf and a full clinical exam each morning to assure the good health of both individuals.

Shortly after the caesarian section the staff and students were confronted with a familiar sight: The patient her vagina had once again prolapsed.

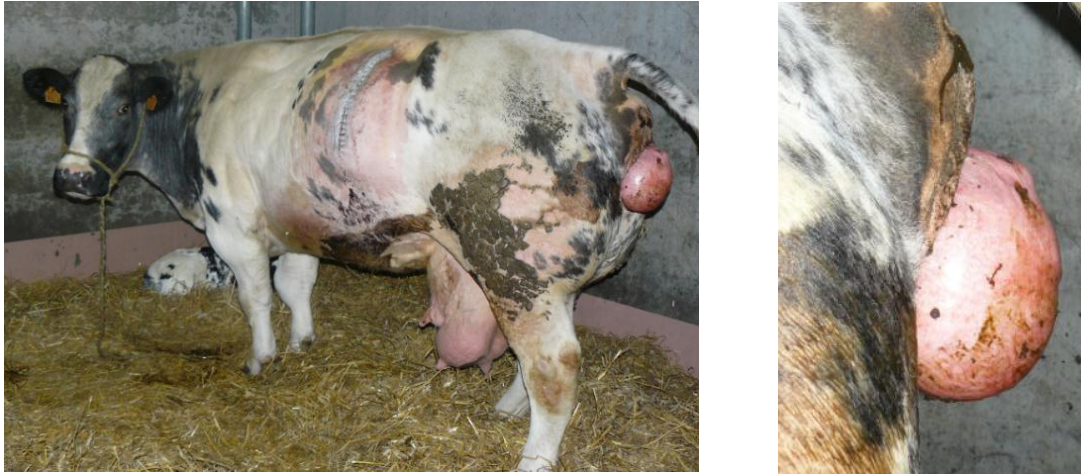

Figure 6: Another vaginal prolapse the day after the caesarean section.

For the three full days during which the cow was hospitalized after surgery, she received the same treatment as when she came in three months earlier. Every time the vagina prolapsed an epidural was placed, hygienic measures were taken and the vagina was massaged back into the pelvic cavity. On the 29th of October the owner finally took his cow home most likely with the intent to bring her to the slaughterhouse as soon as the 28 days of waiting time, instigated by the antibiotics administered during and after surgery, had passed.



Figure 7: Repositioning of the Prolapse

A problematic situation however arises when consulting the law. On the 5th of January EG nr. 1/2005² concerning the transportation of animals was instigated (Kroeze and De Vries, 2008). This law concerns itself with every economically relevant transportation of vertebrates and thus also applies to cows being transported to the slaughterhouse.

EG nr. 1/2005² states that only animals suitable for transportation are to be transported. This same law clearly states that animals with a prolapse of any sort are not considered suitable for transportation. Fortunately there is an alternative way to bring an animal unsuitable for transportation to the slaughterhouse and this after performing an emergency slaughter. The law concerning the concept emergency slaughter was however revised and reinstated on the first of January 2006 (Kroeze and De Vries, 2008). EG 853/2004 in its new form dictates that the maximum time between the occurrence of the prolapse and the emergency slaughter constitutes three days. This would mean that our patient does not qualify for the emergency slaughter.

The above two laws teach us that a cow with a chronic prolapse simply does not enter the slaughterhouse. It must however be mentioned that an exception is made for animals whom are delivered to the slaughterhouse and appear to have prolapsed during transportation (Anonymous, 2010).

What exactly became of the vaginal prolapse cow is not known for certain but an educated guess would be that she is no longer alive today. Although not frequently applied, one must realize that there are options to more adequately treat chronic cases of vaginal prolapse as the methods applied to this patient were only capable of giving temporary relief. This temporary relief was in this case sufficient, as the patient was a commercial cow at the end of her career. However, had the patient been of higher value a more permanent fixation technique such as the Minchev suture, Johnson button or cervicopexy could have been carried out (Miesner and Anderson, 2008).

As for the healthy bull calf, his false due date was probably a simple administrative mistake and he is most likely growing rapidly to fulfill his destiny as beef cattle.

3. The Second Case Report

3.1 The Patient

In the spring of 2010 a Zwartbles ewe approximately 7 years of age was due to lamb for her fifth time. The Zwartbles breed is a breed that finds its origin in the Netherlands. Female representatives of the Zwartbles line are renowned for their high fertility, excellent mothering qualities and easy deliveries (Stouw, 2011). The ewe in question lived up to that reputation as she had thus far successfully delivered and nursed three sets of triples and one set of twins.

Approximately a week before her calculated due date the patient was found with a small vaginal prolapse about 8 cm in size. Because the sheep was kept inside and under close supervision whilst awaiting parturition the prolapse was promptly detected. In the hope that the problem would resolve itself the farmer observed the situation closely for a day. Unfortunately the prolapse worsened quickly during the course of hours and became readily contaminated with feces and soil. As a result hereof the farmer decided to reposition the prolapse and place a Dalton spoon. The prolapse was rinsed with clean water and massaged gently back into the pelvic cavity with the use of sufficient lubricant. Hereafter the Dalton spoon was inserted into the vagina. In order to insure that the device would hold the farmer had created a harness from string to fixate the spoon as he did not believe it sufficient to secure the spoon to the wool.



Figure 8: A Dalton spoon

3.2 The Partus and Postpartum

Important now was that the farmer be present at parturition in order to remove the device.

The approaching parturition in sheep is characterized by changes in both the vulva and the udder. Particularly changes in the udder such as swelling of the glandular tissue and filling of the teat cisterns with milk may already be seen a week or two in advance, as was the case with this patient. Closer to parturition the udder sometimes fills itself to the extent that the teats and udder become very swollen, red, and thick yellow secretion is discharged (De Kruif and Van Soom, 2009).

The first sign of approaching parturition with respect to the vulva is that of slight swelling. Hereafter the vulva starts to become red only to be both red and swollen on the day of parturition (De Kruif and Van Soom, 2009).

In addition the physiological changes that occur prepartum certain behavioral signs are also an important indication for approaching parturition. At the start of parturition an ewe may display the following restless behavior: she will seclude herself from the others, find a sheltered area, alternate lying/standing and paw at the ground frequently sniffing at this area. These periods of activity often occur at 15 minute intervals accompanying abdominal contractions that last approximately 30 seconds (Scott, 2010).



Figure 9: The Patient

Unfortunately the farmer came back from school one day to find the Dalton spoon in a most awkward position with a lamb in anterior position, partially hanging out from the vulva. The spoon had without doubt hindered this lambs expulsion and by the time the farmer came to the scene and removed the spoon the lamb was dead. As not to waste any more time the farmer quickly delivered the two remaining lambs, both where still lying quite deep in the uterus, one in anterior and one in posterior position. After the delivery the ewe remained uncomfortable and failed to stop straining, this naturally led to the beginning of yet another vaginal prolapse. The farmer decided to reposition the beginning vaginal prolapse in the hope that the straining would cease.

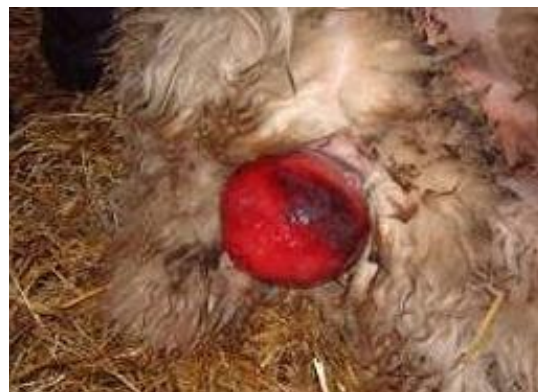

Figure 10: An ewe with a vaginal prolapse

This method however proved inadequate as the vagina almost immediately prolapsed again. Although the prolapse appeared less extensive than before and despite genuine belief of the farmer that his ewe was not suffering too much discomfort, this would have probably been a good moment to consult a veterinarian. The farmer however waited and observed as the vaginal tissue slowly became necrotic and the prolapse grew in size. After three days of observation and with a clear demarcation line formed between the live and necrotic vaginal tissue the farmer consulted his veterinarian.

3.3 Amputation of the Vaginal Prolapse

It was clear to both parties involved that the presence of necrotic tissue excluded the simple repositioning of the vaginal prolapse from the list of options. After taking the necessary hygienic measures and examining the prolapse more closely the veterinarian had formed an alternative plan. A more thorough exploration of the prolapse had led her to conclude that it was only really the vaginal floor that had become necrotic. She therefore decided to simply remove the necrotic tissue, suture the created defect back together and reposition the vagina. In order for her plan to succeed it was important that she worked in healthy vaginal tissue and that the opening of the urethra stayed intact. To find the perfect place for her incision the veterinarian first exerted traction on the vaginal prolapse, causing for the more healthy tissue to become exposed. She then used about 10cc's of procaine and injected small dosages of the anesthetic into the vaginal tissue where she was going to make her incision. With this done she simply took a scalpel and cut off the stump of necrotic tissue. The defect created was sutured back together using a simple continuous stitch and the vagina was repositioned. No additional measures were taken to secure the vagina in place. The ewe was treated with antibiotics (Neopen) for 5 days and the problem appeared to be resolved. It must be mentioned that throughout her ordeal the ewe continued to mother her lambs enthusiastically. Four months after the procedure, the lambs were weaned and the sheep was transported to the slaughterhouse along with the other reform ewes.

4. A Case of Mismanagement

In his recent book, *Sheep Medicine*, Philip Scott expresses his concern for the welfare of sheep. In his many years of experience practicing veterinary medicine he has come to the conclusion that the care and welfare of sheep in the United Kingdom has gradually deteriorated and this largely as a consequence of the poor economical returns from sheep farming. The sensitive balance that exists between animal welfare and economical gain is naturally not only a dilemma in the United Kingdom, but rather a global concern.

The following case that I would briefly like to present is a case of mismanagement of vaginal prolapse in a Texel ewe.

The Dalton Spoon, as discussed above, is a minimally invasive method for treating vaginal prolapse, and placement of the device can easily be carried out by the sheep farmer himself. Other, more invasive methods are however also to the disposal of our farmers. The Texel ewe under discussion suffered a vaginal prolapse several months before her expected lambing date. The farmer in question, a strong believer in the Dalton spoon, decided to combat the vaginal prolapse by inserting this device. Unfortunately the ewe did not respond well to the taken measure, as she continued to strain and prolapse. After several fruitless attempts to keep the vaginal prolapse in place with the aid of a Dalton spoon, the farmer opted for a more invasive method. Instead of consulting a veterinarian he inserted what cannot be better described as a large safety pin, midway through both vulva lips, closed the device and placed his ewe back in the flock.



Figure 11: Device inserted as a measure against vaginal prolapse.

The ewe was found one day amongst the rest of the flock, presumably quite some time after insertion of the safety pin, straining vigorously. The vagina had prolapsed to the extent possible with the retention method undertaken, and was now heavily irritated, soiled and discolored. The penetration wounds of the pin had also become severely infected, and the sheep was overall in very bad shape. Despite this, there was no question of consulting a veterinarian. Eventually measures were taken using the means at hand.

Fortunately everyone agreed that the restraining device could not remain in place. After administering a 2 cc sacrococcygeal extradural injection of Lidocaine and confirming that the ewe no longer reacted to touch of the perineum and vulva, the restraining device was removed.

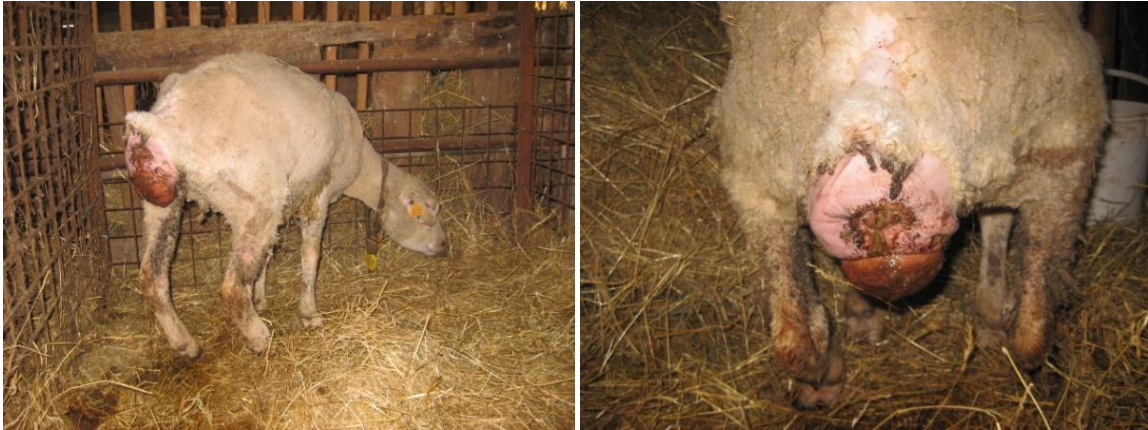

Figure 12 &13: The ewe after removing the 'safety pin'.

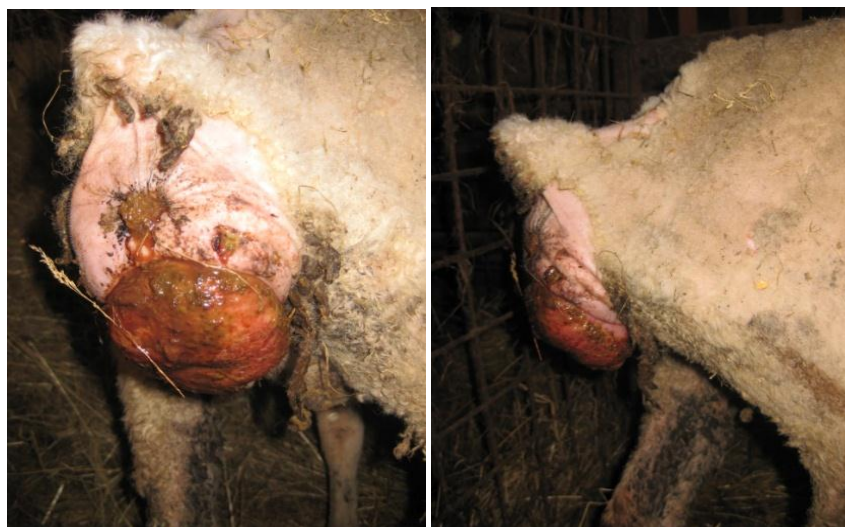

Figure 14 & 15: Close up of the chronic vaginal prolapse.

In a best case scenario it would be expected that the injection with lidocaine would also be able to combat the ewes persistent straining, this was however not the case. When later consulting Jef Laureyns a veterinarian with many years of experience he confirmed that such extensive straining can no longer be combated with a simple epidural.

After rinsing the prolapse with water and cleaning the surrounding area with iodine soap the vaginal prolapse was more closely examined. An examination of the prolapse led to the discovery that the lumen of the vagina had grown closed as a result of persistent straining against the retention device. This finding in combination with the bad state of both the vaginal mucosa and the ewe made the situation quite grave. Fortunately urine passage was still possible but other than that there was little positive to be remarked. The question now of primary concern was how to carry on.

One might be tempted to reposition the prolapse, but when pushing the mass of tissue illustrated above back into the pelvic cavity there is virtually no chance that it will stay in place. Quite frankly even if the tissue did stay in place a clump of heavily damaged and infected vagina stuffed back into the pelvic cavity cannot actually be considered a solution to the problem. A better idea would be to see if

it was possible to reopen the vaginal lumen, to then reposition the prolapse properly and to place a Buhner suture. Unfortunately without the proper means and guidance of a veterinarian it was not even an option to attempt such a plan of action. The farmer eager to collect his lambs and not so eager to spent but a dime further on the sheep thus decided that it was best to simple wait and see what happened.

Judging from the state of the ewe I for one doubted that she was pregnant, and even if this is the case, the closed vaginal lumen will probably mask her beginning labor, making it highly likely that the lambs will be dead dead by the time a caesarean section takes place. In my modest opinion there is only one proper solution to the situation and this is euthanasia. Unfortunately up until a few weeks ago the sheep with the vaginal prolapse was still just standing there awaiting a parturition that will either never take place or that will end up a disaster.

5. Literature Review/Discussion

5.1 Anatomy and Fixation of the Vagina

Vaginal prolapse most frequently affects ewes and cattle in their last trimester of pregnancy. It is believed that the vagina undergoes a varying degree of relaxation as a result of the hormonal changes ascribed to late term pregnancy. The same theory upholds for the soft tissues associated with the vagina, more specifically the related muscles, ligaments, synovial membranes and fascia, undergo a varying degree of relaxation as a result of the hormonal changes ascribed to late term pregnancy (Kahn, 2009). When combining this tissue relaxation with an increased abdominal pressure brought about by the pregnant uterus, a risk for vaginal prolapse is created.

With the belief that soft tissue relaxation plays a dominant part in the pathogenesis of vaginal prolapse, a better understanding of the anatomy of the vagina and its related soft tissues appears relevant.

5.1.1 The Vagina

The vagina, with its tube like structure, is considered the cranial part of the female copulatory organ extending from the external uterine ostium to the entrance of the urethra. The vagina is located in a medial position in the pelvic cavity underneath the rectum and above the bladder. For the most part the vagina is located retroperitoneally but the most cranial part is covered in peritoneum. The cervix located cranially to the vagina restricts the lumen of the cranial vagina to a ring-like space known as the fornix (König and Liebich, 2004).

The vestibulum vaginae constitutes the caudal part of the female copulatory organ extending from the ostium urethral opening to the external vulva. In cows the urethra forms a central evagination, the suburethral diverticulum which opens together with the urethra into the vagina, complicating catheterization of the urinary bladder. The vestibulum lies for the most part behind the ischial arch and slopes ventrally towards its opening in the vulva, this ventral sloping must be taken into consideration when inserting a speculum or any other device into the vagina. Vestibular glands are contained in the wall of the vestibulum and the secretion thereof facilitates parturition and coitus. Minor vestibular glands are also present in the sheep and cow additionally. In both the cow and the ewe a large glandular mass is present on both sides of the vestibulum (König and Liebich, 2004).

Anatomically speaking the vulva and the vestibulum vaginae are well fixated whilst the contrary can be said about the vagina. The caudal part of the vagina is surrounded by loose fatty tissue and connective tissue and is hereby fixated to a certain extent, whilst the cranial part of the vagina is subject to very limited fixation (De Kruif and Van Soom, 2009).

5.1.2 The Ligaments

The main attachment of the female genital organs is provided by the ligamentum latum uteri, also known as the broad ligaments of the uterus. Seeing as the broad ligament suspends the uterus in addition to both ovaries and ovarian ducts, it can be divided into three parts: the mesovarium, the

mesosalpinx and the mesometrium. The broad ligaments are actually paired double folds of peritoneum and the serosal membranes are separated by a large amount of tissue, consisting mainly of smooth muscle from the longitudinal layer of the myometrium. This unique structure allows for the ligament to play an active role in supporting the uterus. The largest part of the ligamentum latum is the mesometrium which attaches to the uterus and the cranial part of the vagina. At the site of attachment of the cervix and vagina the serosal membranes of the mesometrium are widely separate. In addition to the broad ligament several other ligaments, are associated with the female genital tract, the suspensor ligament of the ovary, the proper ligament of the ovary and the round ligament of the uterus. These are however of lesser importance (König and Liebich, 2004).

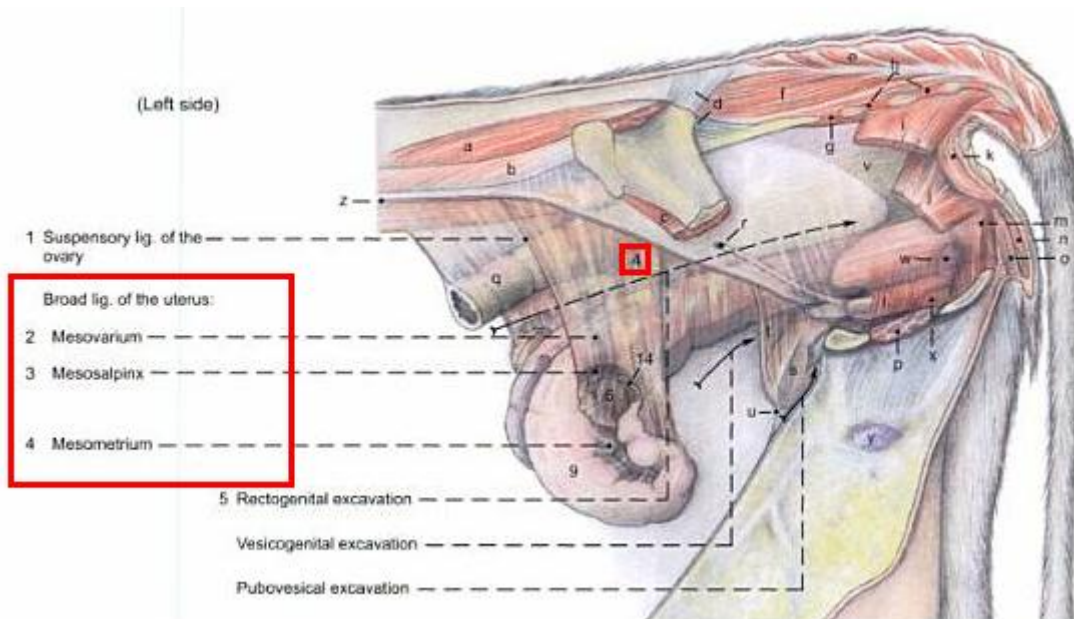


Figure 16: Ligamentum Latum Uteri in a cow (Budras and Habel, 2003).

5.1.3 Muscles and Fascia

The pelvic outlet is closed by a musculo-fascial partition, which is divided into the pelvic diaphragm dorsally and the urogenital diaphragm ventrally. The urogenital diaphragm closes the pelvic outlet around the vestibulum vaginae whilst the pelvic diaphragm closes the pelvic outlet around the anus (König and Liebich, 2004).

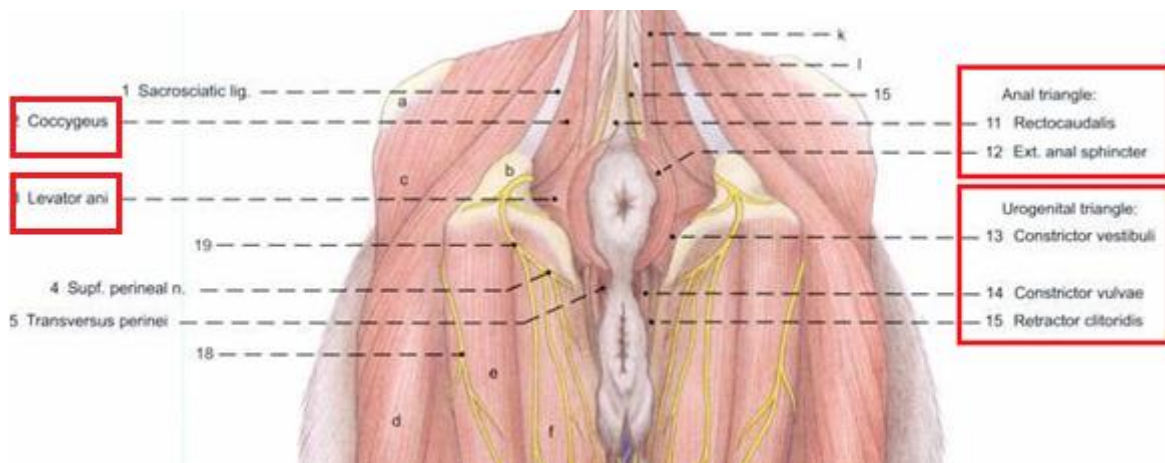


Figure 17: Muscles of the pelvic diaphragm in a cow (Budras and Habel, 2003)

The pelvic diaphragm, also named the anal triangle is composed of the m. coccygeus the levator ani muscle and the external anal sphincter. The urogenital diaphragm or triangle, is composed of a strong perineal membrane which extends from the ischial arch to the ventral and lateral walls of the vestibulum vaginae attaching cranially to the constrictor vestibule and caudally of the major vestibular gland. The perineal membrane together with the urogenital muscles (m. constrictor vestibule m. constrictor vulvae and m retractor clitoris) forms the urogenital triangle and fuses with the pelvic triangle at the level of the perineal body hereby anchoring the genital tract to the ischial arch (Budras and Habel, 2003).

5.2 Causes of Vaginal Prolapse

Vaginal prolapse is a frequently occurring phenomena in both sheep and cattle. When it comes to the causes of vaginal prolapse genetic, nutritional and hormonal components have all been linked with the problem in question. Unfortunately there is a lot that still remains unknown about the causes of vaginal prolapse.

5.2.1 Hormone Profile's and Vaginal Prolapse.

With vaginal prolapse most frequently occurring during the last trimester of pregnancy it is believed that the hormonal alterations taking place at this stage are of primary importance in facilitating vaginal prolapse (Wolfe 2009). The hormones most relevant to this theory are: estrogen, relaxin and progesterone.

That estrogen plays an important role in preparing the genital tract and surrounding tissues for parturition was already illustrated early on when research linked insufficient levels of estrogen to dystocia (Osinga, 1978). Amongst its many other effects, the importance of estrogen during gestation, is found in its action on the pelvic ligaments and surrounding soft tissue structures. Relaxation of the pelvic ligaments and surrounding soft tissue structures is a gradually occurring process during pregnancy but becomes far more outspoken towards the end of gestation due to rising estrogen levels in combination with the production of relaxin (Hafez E.S.E and Hafez B, 2003).

When consulting literature to further understand the role of progesterone in the occurrence of vaginal prolapse, little information appears to be available. The practice of administering exogenous progesterone in aiming to avoid vaginal and cervical prolapse however implies that it is believed that sufficient levels of progesterone are important in the prevention of vaginal prolapse (Tandon, 2003).

In pregnant cows a steady increase of progesterone is documented during pregnancy until levels of around 13.9 ng/ml are detectable in peripheral plasma, at this stage progesterone levels remain rather constant for the remaining duration of the pregnancy. During the 14 days before parturition, estrogen increased from 500 pg/ml to 2660 pg/ml at parturition. For the last 5 days, the estrogen concentration progressively increased at the rate of 248 pg/day. During this period, progesterone remains relatively steady at one-third the level observed during early pregnancy until 1 day before parturition, when it falls to 0.7 ng/ml (Hendricks et al., 2011).

In ewes a more gradual increase of the progesterone level in peripheral plasma is observed during pregnancy. The maximum progesterone plasma levels are reached at about day 140, and are logically dependent upon the amount of fetuses being carried. The mean progesterone plasma value in an ewe, carrying one lamb lies around 13.2 ng/ml, and in twin pregnancies values of around 20.0 ng/ml have been documented. During the last week of pregnancy a marked decline in plasma progesterone levels is observed with a mean value of 2.1 ng/ml at parturition (Fylling, 1970). As described in cows, plasma estrogen levels in sheep also rise drastically towards the end of gestation in order to peak at parturition (Sjaastad et al., 2003).

A study of the progesterone and estrogen concentrations in blood plasma of ewes suffering from vaginal prolapse revealed the following: "The average progesterone concentration of affected ewes was above those of control animals ante and intra partum. However, no significant differences were observed. The plasma levels of 17β -estradiol in animals suffering from ante partum vaginal prolapse were increased in comparison to the values of the pregnant control group, but were without statistical significance." (Ennen et al., 2011).

The raised progesterone levels in affected ewes may lead one to question the initial proposal that progesterone plays a preventative role in the pathogenesis of vaginal prolapse. However the registered progesterone and estrogen concentrations are the results of a single study. The found hormone levels are not even of statistical significance and they definitely do not help us any further with the question of how these two hormones do or do not contribute to the pathogenesis of vaginal prolapse.

In an attempt to clarify the role of estrogen in the occurrence of vaginal prolapse, a theory was formed suggesting that an increased expression of estrogen receptor α in the genital tract may facilitate an increased estrogenic effect resulting in vaginal prolapse. Ennen and her research group however found that the expression rate of estrogen receptor α was lower in the animals suffering a vaginal prolapse compared to the healthy control group. Although there is potentially only one study contradicting the hypothesis that an increased expression of estrogen receptor α in the genital tract may be the route by which estrogen facilitates vaginal prolapse, there is no study found confirming the theory either. The only conclusion that can be drawn from this is that the answer still remains unknown.

At this stage it is important that one remains objective and realizes that there is simple to little research done with respect to the role of hormones in the pathogenesis of vaginal prolapse, to enable concrete conclusions to be drawn. When looking at the situation from a practical point of view, although maybe not scientifically proven, the general believe still rests that high levels of estrogen facilitate vaginal prolapse. In the end this is not such a foolish thought as one can come to the conclusion using pure logics. The hormone estrogen relaxes the pelvic ligaments and surrounding soft tissue, hereby causing a decreased fixation of the vagina. When combining this decreased vaginal fixation with an increase of intra abdominal pressure such as found in highly pregnant animals, the vagina is more inclined to prolapse. Another, more concrete argument illustrating the importance of estrogen in the occurrence of vaginal prolapse, is the fact that cows suffering from cystic ovarian disease are more susceptible to developing a vaginal prolapse. More specifically cows suffering from follicular cysts,

especially those exhibiting extreme signs of nymphomania, have been known to suffer a vaginal prolapse. The follicular cyst creates a hormonal environment in which progesterone is limited whilst the production of estrogen exceeds the norm (De Kruif and Van Soom, 2009). Well developed follicular cysts such as the ones present in nymphomaniac cows thus provide the estrogen rich environment believed to facilitate the occurrence of vaginal prolapse.

When examining the role of relaxin in the cause of vaginal prolapse, the hormone can be linked to the pathogenesis in a way similar to that of the hormone estrogen, namely through the weakening of the soft tissues associated with the vagina.

Relaxin is a hormone that remodels connective tissue hereby inducing cervical dilation, pelvic relaxation, and separation of interpubic ligaments in several mammalian species (Lloyd, 2011). Experiments performed on rats acknowledged significant decrease in collagen levels during pregnancy and parturition coincide with a rapid increase in serum relaxin levels during this time. (Sherwood & Crnekovic 1979, Sherwood *et al.* 1980). The reduction in collagen content may be attributed to collagen degradation through activation of the collagenolytic but the spectrum of collagen types remains unchanged throughout gestation (Samuel et al., 1998). The production of this hormone in pregnant ruminants is low. Non ruminants also maintain low relaxin levels during most of the pregnancy. Analysis of the plasma samples of sows, however illustrates a surge of relaxin production during the last week of gestation, peaking at levels of 60-90 ng/ml on the day of parturition (Lloyd, 2011).

When carrying out the same analysis in blood plasma samples of pregnant cattle we learn that levels of relaxin secreted during the last week of pregnancy are still quite low with values of 0.20 ng/ml representing the mean. On the day of the partus relaxin however also increases and peaks at concentrations greater than 0.800 ng/ml (Lloyd, 2011).

In sheep, relaxin plasma concentrations increase with advancing gestation, from an average of .60 ng/ml reaching a peak of 3.90 ng/ml four days before parturition. At parturition however, relaxin concentration averaged only .80 ng/ml (Lloyd, 2011).

From this data we learn that although an antipartum relaxin surge does occur in sheep, the relaxin peak occurs earlier than in non ruminants. When comparing the plasma concentration of relaxin registered in cattle with the relaxin surge and peak undergone by non ruminants, the term hardly seems applicable to cattle.

Despite completely different measures of relaxin in the blood for different species, the above information does illustrate that both cattle and ewes are influenced by relaxin during pregnancy. Knowing a little bit better the mechanism by which relaxin functions, yet again lacking evidence linking relaxin to vaginal prolapse in a more concrete way, we end up with a conclusion much like the one drawn earlier on concerning our hormone estrogen. Relaxin breaks down collagen in the pelvic ligaments and surrounding soft tissue, hereby weakening the connective tissue and thus causing a decreased fixation of the vagina. When combining this decreased vaginal fixation with an increase of intra abdominal pressure such as found in highly pregnant animals, the vagina is more inclined to prolapse.

5.2.2 Vaginal Prolapse a Hereditary Trait

It would be nice to be able to say that vaginal prolapse is a hereditary trait located on chromosome x more specifically in gene coding region y. Unfortunately the basis for the believe that vaginal prolapse has a genetic foundation is not quite this concrete. It is however assumed that the occurrence of vaginal prolapse has a genetic foundation in both cattle and sheep (Kahn, 2005). This assumption is based upon the more frequent observation of the pathology in certain breeds and bloodlines. In cattle for instance Brahman, Brahman crossbreds and Hereford appear predisposition, whilst in sheep Kerry Hill an Romney Marsh ewes seem more inclined to suffer from a vaginal prolapse. A survey conducted in 1985 obtaining information on almost 1000 flocks in Scotland revealed a clear difference in the prevalence of vaginal prolapse between the various local breeds and there crosses. The flocks of pure bred country cheviots and scottisch blackface ewes, appeared relatively unaffected by vaginal prolapse. Greyface ewes (Borderder Leicters crossed with Scottisch blackface) or Mule ewes (Blueface leicester crossed with scottisch blackface) mated to suffolk rams however showed a high incidence of vaginal prolapse.

Tup Breed	Ewe breed	% Prolapse
South country cheviot	South country cheviot	0.1
Scottisch blackface	Scottish blackface	0.2
Bluefaced Leicester	Scottish blackface	1.4
Suffolk	Greyface and mule	1.8
Suffolk	Halfbred	1.0
Suffolk	Suffolk	1.4

Figure 18: Percentage of vaginal prolapse in different breeds of sheep (Low and Sutherland, 1987).

Sutherland and Low, in a more detailed analysis of their results also suggested that certain families within breeds are particularly susceptible to vaginal prolapse. Other studies such as the one mentioned above along with many professional experiences all come together to support the fact that vaginal prolapse is a hereditary trait.

When crossing over into the field of medicine where vaginal prolapse is also an occurring problem, it is likewise believed that the problem is partially genetic. Through studying family trees of affected individuals, thus by a method similar to that applied in veterinary medicine, these ideas where formed and developed. Take for instance the results of a study done on the genetics of genitovaginal prolapse in 2005 by Jack et al. By identifying ten young patients with a history of vaginal prolapse and drawing up a few family trees, the following conclusions were drawn: "Genetic analysis of the inheritance pattern within these families demonstrated that pelvic organ prolapse segregated in a dominant fashion with incomplete penetrance in these families. Both maternal and paternal transmissions were observed. The relative risk to siblings of affected patients was five times that of the risk for the general population." (Jack et al., 2005).

A simple observation of trends has for instance taught us that daughters of mother cattle suffering from vaginal prolapse have an increased likelihood of suffering a vaginal prolapse themselves (Powell, 2005). The advice to cull both mother and daughter would therefore by many be considered the correct measure. In addition, bull calves of affected mother animals have been suggested capable of passing on the trait to female offspring and should therefore not be used for breeding (Powell, 2005). Over the years it has become common practice to cull all ewes with a vaginal prolapse (Scott, 2010). Culling every affected ewe hardly seems like the most economical method of action and I hardly believe farmers would apply it, had experience not taught them that it is simply the right thing to do.

Maybe we cannot quite pinpoint the exact location of the disease on a chromosome but in my opinion the information known to us right now sufficiently pleases for the fact that the occurrence of vaginal prolapse has a hereditary component.

5.2.3 Collagen Metabolism and Vaginal Prolapse

In 2004 a study by Söderberg et al., revealed that human patients suffering from vaginal prolapse appeared to have up to a 30 percent lower concentration of collagen. This conclusion was drawn after the analysis of punch biopsies taken from the paraurethral ligaments of 22 prolapse patients undergoing surgery. In 2007 Twiss et al., published an article believing to have identified the gene responsible for the genetical foundation playing a part in many vaginal prolapse cases. The gene in question was LAMC-1 and it codes for a subunit of the laminin protein, that amongst other things, contributes to the structural integrity of the extracellular matrix (Twiss et al., 2008).

In 2011 Ennen and her research group made a similar breakthrough concerning the occurrence of vaginal prolapse in ewes. By doing a biomolecular analysis of the connective tissue of several ewes, with and without vaginal prolapse, it was hoped to illustrate that the occurrence of vaginal prolapse in these animals could also be linked to alternations in vaginal connective tissue.

Connective tissue consists of both a cellular and an extracellular matrix. It is mainly this extracellular matrix held responsible for giving stability. More specifically, collagen I and III of the extracellular matrix make up an important part of vaginal and cervical tissue (Jeffrey, 1991).

Biopsies were taken from the vaginal tissue and analyzed for the mRNA-expression and transcription levels of the α_2 -chain of collagen I, the collagenolytic metalloproteinase 1 (MMP-1) and the tissue inhibitor of MMP-1 (TIMP-1).

The Matrix Metalloproteinase's such as MMP-1 play a role in the rearrangement of connective tissue as they are capable of degrading collagen fibers. Tissue Inhibitor proteins such as TIMP-1 are in turn inhibitors of MMP's. TIMP-1 for instance actively binds to MMP-1 hereby inhibiting its collagenolytic function (Timmerman, 2005).

The results of the analyses of mRNA expression and transcription levels of, MMP-1 and TIMP-1 were as followed: "The average mRNA synthesis of MMP-1 and TIMP-1 in affected ewes varied from those in healthy, pregnant sheep by a higher and/or lower level respectively, but significant differences were not apparent." (Ennen et al., 2011). Although the author is aware that the results obtained were not statistically significant, she does recognize that the increased expression of MMP-1 and the decreased expression of TIMP-1 are indicative for an increased catabolism of collagen. Caution is however

required in drawing up this conclusion as enzymes and their inhibitors are capable of undergoing posttranscriptional modifications. The MMP-1's are for instance secreted in their inactive form only to be activated at their target destination. In addition to this, the TIMP-1 molecules, although most commonly functioning as inhibitor, are also capable of having activating effects depending upon their concentration (Clark et al., 1994). Nevertheless Ennen concludes that: "the mRNA expression rate of TIMP-1 and MMP-1 can be seen as an indicator for the dysfunction of the collagen metabolites."

In addition the result concerning the mRNA expression of α_2 -chain of collagen 1 indicated a statistical difference between afflicted animals and the pregnant control group. More specifically the expression of α_2 -chain of collagen 1 was lower in ewes with prolapsed vaginal tissue. Because of the fact that collagen one is actually composed of two α_1 , and one α_2 -chains connected to a triple helix the author warns that the decreased expression of the α_2 -chain of collagen 1 does not necessarily indicate a reduced protein biosynthesis and therefore a reduction of collagen in the vaginal wall. Because single collagen chains undergo translational modification before able to form a triple helix, regulation not only occurs at the level of transcription but also at the level of protein synthesis (Olsen and Ninomiya, 1999).

Despite some potential reservations, the research that Ennen et al., conducted led to the following general conclusion: "Affected ewes show alterations in the antepartal metabolism of vaginal connective tissue... Further research involving expression studies might offer perspectives concerning therapy and prevention of this economically important clinical condition."(Ennen et al., 2011).

5.2.4 Vaginal Prolapse and Nutrition

Nutrition is commonly listed as a factor contributing to the prevalence of vaginal prolapse. More specifically, poor quality forage, high levels of concentrate, high estrogenic-content feeds and hypocalcaemia have all been associated with the pathology (Miesner and Anderson, 2008).

Additionally there appears to be a correlation between obesity and the occurrence of vaginal prolapse (Hosie et al., 1999).

Distributing poor quality forage will require for ewes to increase their feed uptake in order to meet their energy requirements. This increased uptake of forage however results in an increased ruminal filling, which in turn contributes to a higher intra-abdominal pressure hereby predisposing for vaginal prolapse (Pelzer, 2008).

The same disadvantage however has been experienced by herders feeding alfalfa hay (Umburger, 1991). Due to the products high quality and palatability, ewes consume more alfalfa hay than is needed. The bulkiness of the hay in the rumen can, by the same mechanism as poor quality forage, place pressure on the reproductive tract, resulting in a vaginal prolapse.

The feeding of excessive amounts of concentrates has also been associated with the occurrence of vaginal prolapse. The initial concern that one may have when it comes to the feeding of concentrates to cattle and sheep, is that of overfeeding, as this may lead to ruminal acidosis.

Due to the uptake of rapidly fermentable carbohydrates the ruminal pH shall, as a result of the products of fermentation, quickly begin to drop. This drop in pH causes a shift in the ruminal flora from

cellulolytic to lactic acid producing bacteria, hereby further accelerating the prior established decline in ruminal pH.

The realized pH change directly undermines the integrity of the ruminal wall. Meanwhile the rapid fermentation of food causes the ruminal content to become more osmolar. The damage caused to the ruminal wall, in combination with the hyperosmolarity of the ruminal content, instigates a diffusion of fluid from the circulation into the rumen. This diffusion brings about a ruminal distention that is further enhanced by the accumulation of gas formed during fermentation (Deprez, 2009).

In addition to the many complications and symptoms that ruminal acidosis presents, vaginal prolapse is a side effect that is maybe not directly considered but that can also be associated with the pathology. It is the ruminal distention resulting from acidosis, that once again contributes to the formation of that higher intra-abdominal pressure known to facilitate vaginal prolapse. Of course in a case of acute ruminal acidosis one is more likely to fear for the life of the sheep than for a vaginal prolapse, yet in more chronic cases of ruminal acidosis one can imagine that vaginal prolapse may become a part of the pathogenesis. Alternatively one may consider that a vaginal prolapse severe enough to compromise a patient's health may actually be the cause of sub acute ruminal acidosis. Unwell patients often decrease their uptake of roughage whilst still eating their initial amount of concentrates an amount that suddenly constitutes a much larger percent of their diet.

When following the general trend it becomes clear that any cause for an increased abdominal pressure appears to predispose for the development of a vaginal prolapse. Aside from the nutritional factors listed above, other factors capable of increasing intra-abdominal such as intra-abdominal fat accumulation, large fetuses, multigravid uterus, hilly terrains, the manipulation of sheep before shaving or claw treatment, limited exercise and lameness leading to long periods of sternal recumbency therefore all also make their contribution to the occurrence of vaginal prolepses' (Drost, 2007 and Scott, 2010).

Having previously elaborated upon the role that estrogen plays in the pathogenesis of vaginal prolapse, it is a logical next step to link feeds high in phytoestrogens with the occurrence of vaginal prolapse.

Phytoestrogens, are plant derived components that structurally or functionally mimic mammalian estrogen (Osoki and Kennelli, 2003). The biological activity of phytoestrogens is diverse. This diversity can be partially attributed to the ability of phytoestrogens to act as both estrogen agonists and antagonists thus causing either an estrogenic or antiestrogenic effect. The means by which this is accomplished varies, thus far both genomic and nongenomic pathways of action have been identified (Anderson et al., 1999). It has been suggested that the levels of endogenous estrogen contribute to determining the actions of phytoestrogen as it is believed that phytoestrogens go into competition with the endogenously available estrogens (Folman and Pope, 1966). In ewes for instance, the activity of endogenous estrogen is considered low and phytoestrogens have been reported to function primarily as estrogen agonist, whilst in humans whom are considered to have high levels of endogenous estrogen, the antiestrogenic effect of phytoestrogen appears to predominate (Adlercreutz et al., 1991). Cattle also exhibit low levels of estrogen and one shall thus expect phytoestrogens to act primarily as estrogen agonists thereby causing an estrogenic effect (Adams, 1995).

The presence of phytoestrogens has been reported in many legumes some of which are frequently present on pastures. Prime examples of estrogenic feeds are alfalfa, red clover, white clover, subterranean clover and soybean (Adams, 1995). Signs of estrogenism such as a swollen vulva, cervical mucus discharge, behavioral changes and mammary development seen in cattle consuming, what was later to be discovered as being high estrogenic feeds, first drew attention to phytoestrogens. At this stage the consumption of these phytoestrogens was linked to infertility based on a pure confirmation of trends: fertility was low when animals consumed phytoestrogens but the problem resolved after removing the estrogenic feeds. An extensive scientific approach to the problem has years later formed a more solid explanation for earlier accounted events.

In a normal situation estradiol-17- β is, amongst other things, responsible for modulating the uterine prostaglandin production (mainly PGF2 α luteolytic and PGE luteotropic) (Woclawek-Potocka et al., 2005). These prostaglandins in turn play a crucial part in modulating the normal cyclicity of the bovine reproductive organs. Phytoestrogens were more concretely linked to infertility because they are, just like estradiol-17- β , capable of promoting Prostaglandin synthesis in the endometrium. Woclawek-Potocka and her research group extensively examined the effect of phytoestrogens on prostogladin production and found the following: "Phytoestrogens stimulate both PGF2 α and PGE2 in both cell types of bovine endometrium via an estrogenreceptor-dependent genomic pathway. However, because phytoestrogens preferentially stimulated PGF2 α synthesis in epithelial cells of bovine endometrium, they may disrupt uterus function by altering the PGF2 α to PGE2 ratio. This action of phytoestrogens on PGF2 α may account, at least in part, for the reproductive disorders observed in ruminants." (Woclawek-Potocka et al., 2005).

In sheep the consumption of phytoestrogens was historically also linked to a range of abnormalities including a decreased fertility rate and vaginal prolapse (Pugh, 2002). More extensive research eventually recognized that a segregation must be made between temporary and permanent infertility both of which are brought about by the consumption of phytoestrogens by ewes. Ewes suffering from temporary infertility generally undergo a decrease in ovulation and conception rate. In addition to this swelling of the udder or reddening of the vulva may be noticed. Nevertheless, the pathology is frequently subclinical. Temporary infertility will resolve itself after several weeks when moving the ewes to non-estrogenic pastures (Adams, 1995).

Permanent infertility is brought about by a prolonged exposure of ewes to estrogenic pastures. The explanation for this is found in the histological alterations that take place in the cervical tissue of the ewe. In ewes unlike in most mammals the genes controlling sexual differentiation are not fully deactivated at birth, when exposed to estrogen for a longer period of time, the adult ewe gradually loses its sexual characteristics in a manner similar to the sexual differentiation process undergone by male lambs in utero (Adams, 1990). More specifically the cervix seems to undergo a uterus like differentiation. This differentiation is histologically characterized by an increase in both glandular tissue, lamina propria and stratified epithelium cells (Adams and Saunders, 1993). Consequently the characteristic cervical folds diminish hereby hindering the cervix in the normally transportation of spermatozoa after insemination (Lightfoot et al., 1967).

Despite the fact that it is a logical next step to link feeds high in phytoestrogens with the occurrence of vaginal prolapse concrete scientific research on the matter is not currently available. The above information however explores the research that is available concerning phytoestrogens and their ability to affect both sheep and cattle. What we can learn from this information is that phytoestrogens are definitely capable of interfering with the reproductive capacities of our target species. In cattle it has even been proven that phytoestrogens utilize the endogenously present estrogen receptors to realize their estrogenic effect. The thought that phytoestrogens are therefore capable of causing a weakening of the pelvic ligaments and surrounding soft tissues by similar mechanisms is thus not such a random thought when knowing what phytoestrogens have proven to be capable of.

To conclude this section on the nutritional causes of vaginal prolapse it is necessary to mention one more potential cause of vaginal prolapse associated with feed: mycotoxines. More specifically it is the toxin zearalenone that is linked to estrogenism and vulvovaginitis in both sheep and cattle (Kahn, 2005). Zearalenone are toxins produced by various species of *Fusarium* molds. *Fusarium* species are very common in moderate climates under humid weather conditions and often contaminate growing plants or stored feeds such as corn, wheat and barley. Zearalenone and its metabolites bind to the estradiol-17- β receptor and this complex binds to the estradiol site on the DNA where specific RNA synthesis leads to signs of hyperestrogenism. An intoxication with zearalenone toxin has signs identical to an over administration of estrogen such as swelling of the vulva, prolapse of the vagina uterus or rectum and reproductional dysfunctions (Croubels and De Backer, 2009). In order to diagnose the pathology a chemical analysis of the suspected feed for zearalenones is required. Unless the animals are chronically affected signs have a tendency to regress up until a month after exposure to the toxin (Kahn, 2005).

5.3 Assessment of the Vaginal Prolapse

As already mentioned in the introduction, a vaginal prolapse begins just cranially of the vestibulovaginal junction as a folding of the vaginal floor. The discomfort caused by this eversion in addition to the resulting irritation and swelling of the vaginal mucosa, is the start of a vicious cycle characterized by increased straining and the formation of a more extensive prolapse (Kahn 2005). In mild cases one may simply see an intermittent prolapse of the vagina, with the vagina most commonly protruding from between the vulva lips when the animal is lying down (Miesner and Anderson, 2008). In extreme cases the entire vagina may prolapse with the cervix displaying itself at the most caudal part of the prolapse.

Before further examining the vaginal prolapse, it is required to take certain hygienic measures. The area surrounding the prolapse must be washed and disinfected using a mild form of antiseptic (e.g. isobetadine soap or chlorhexidine) Hands must also be washed and disinfected, if preferred gloves may be worn. Furthermore the prolapsed tissue must be rinsed clean with tepid water also containing a mild antiseptic. When the necessary hygienic measures have been taken the vaginal prolapse can be more extensively examined in order to gain a better understanding of the situation.

A mild vaginal prolapse may not directly be considered an emergency, but if not treated, the vagina becomes swollen, edematous and congested and is therefore very susceptible to injury (Hosie, 1989). Considering the fact that the vaginal mucosa is easily undermined, a seemingly innocent prolapse

therefore has the potential to rapidly progress towards a rupture of the vaginal wall. Additionally, as the duration of the prolapse increases vascular compromise, trauma and fecal contamination may result in an increased uptake of toxins via the vaginal mucosa, hereby undermining the patients general clinical condition (Scott and Gessert, 1998). Seeing as the prognosis of a vaginal prolapse can quickly become solemn, it appears sound advice to respond to any vaginal prolapse timely and with care.

Additional complications such as the containment of the bladder within the prolapsed vagina may also require more urgent attention. Not only does the bladder potentially hinder repositioning of the prolapse, it is quite likely that a consequential obstruction of the urethra results in the distention of the bladder and in a worst case scenario a bladder rupture. Other structures such as the intestines and the uterus may also be contained in the vaginal prolapse. A spontaneous rupture of the vaginal wall with herniation of the intestines, bladder or uterus, therefore also belongs on the list of complications to be associated with vaginal prolapse (Veeraiah and Srinivas, 2010). Additionally when persistent straining occurs a vaginal prolapse is sporadically accompanied by a rectum prolapse (De Kruif and Van Soom, 2009). It is important to note that sheep more frequently suffer from complications in association with vaginal prolapse than cattle (De Kruif and Van Soom, 2009).

Although not commonly carried out in cattle, in ewes the ultrasound is occasionally consulted to analyze the content of the vaginal prolapse. With the hygienic measures still in place contact gel or even obstetric lubricant can simply be applied to the prolapse and a quick ultrasound examination can be performed. Not only does the visualization of the content of the vaginal prolapse allow for a better assessment of the situation, the information obtained with this exam is especially relevant if needle decompression of a suspected fluid filled viscus is to be attempted before replacement of the vaginal prolapse. Care must be taken when undergoing such measures as puncturing the allantochorion could introduce infection hereby endanger the pregnancy. Additionally if the uterine horn is contained within the prolapse the risk of puncturing a major blood vessel exists (Scott, 2010).

What must not be overlooked when confronted with a case of vaginal prolapse is the general clinical condition of the patient. To what extend does the patient appear hindered by the vaginal prolapse? Is the patient straining heavily? Does the patient appear to be suffering from additional clinical abnormalities? Especially when dealing with ewes, the time must be taken to perform a quick general exam. Findings such as; an increased pulse, inappetite, an increased respiration rate, signs of toxemia and congested mucous membranes may indicate fetal death and impending abortion, both known complications of vaginal prolapse in ewes (Scott and Gessert, 1998).

If an individual fails to notice that an ewe is threatening to abort and that individual repositions the vaginal prolapse whilst it is heavily contaminated and edematous it is possible that abortion of the fetuses is hindered and that fetal autolysis will rapidly lead to toxemia and death of the ewe. The same theory upholds when further measures are taken to retain a fresh vaginal prolapse. To prevent such complications the farmer should keep his ewe under close supervision, paying special attention to the cervix and the nature of any discharge. An additional measure undertaken by some practicing veterinarians is the assessment of the viability of the fetuses. Using echography an attempt can be made at detecting a fetal heartbeat and fetal movement. Because the fetal heartbeat can be difficult to detect in near-term fetuses it is said that if no fetal movement is detected after five minutes of

searching it is very likely that the fetuses are dead. Knowing this information hopefully stimulated the farmer to keep an extra close watch over his ewe in order to timely detect signs of impending abortion. Some parties may even opt to deliver the dead fetuses via a caesarean section hereby greatly increasing the ewes chances of survival (Scott, 2010).

Wolfe, in his book on large animal urogenital surgery constructed a clinical grading scale for vaginal prolapse in cattle. The scale recognizes four different types of vaginal prolapse and pending upon the situation suggests a course of action.

Grade	Description	Relevance	Treatment
I	Intermittent prolapse of vagina; most commonly when lying down.	Likely to progress to Grade II if not treated	Temporary retaining suture; cull after calving or perform permanent fixation technique if embryo flush cow.
II	Continuous prolapse of vagina ± urinary bladder retroflexed.	Urinary bladder involvement (common) can obstruct urination or cause persistent straining.	Temporary retaining suture; cull after calving or perform permanent fixation technique if embryo flush cow.
III	Continuous prolapse of vagina, urinary bladder and cervix (external os visible)	Can cause compromise to urine outflow and ureters. Should be treated quickly to prevent life-threatening injury.	Perform permanent fixation technique if embryo flush cow. Induce parturition or perform elective C-section if commercial cow.
IV	Grade II or III with trauma, infection, or necrosis of vaginal wall. a. Sub acute such that replacement into vaginal vault is possible. b. Chronic with fibrosis such that the vagina cannot be replaced.	Grade IV a: repair laceration, debride wounds, treat infection, and replace into vaginal vault. Grade IV :b Requires elective C-section or vaginal resection.	Perform permanent fixation technique if embryo flush cow. Induce parturition or perform elective C-section if commercial cow.

Figure 19: Clinical grading scale for vaginal prolapse (Wolfe and Carson, 1999).

5.4 Replacement of the Vaginal prolapse

After having assessed both the patient and the vaginal prolapse it is necessary to choose an adequate course of action. When concentrating solely on the vaginal prolapse one can begin by distinguish between an acute and chronicle vaginal prolapse.

5.4.1 Acute Vaginal Prolapse

If the verdict sounds that the prolapse is acute and the vaginal mucosa is in good condition it is time to reposition the vaginal prolapse and to select the most appropriate fixation technique. As discussed in case one, it is sometimes desirable to simply reposition the vaginal prolapse and to combat any recurrence by minimally invasive methods, such as raising the hindquarter of the patient, placing a Dalton spoon or placing the patient in a harness. Most frequently however, the utilization of a more permanent retention technique is desired

5.4.1.1 Epidural Anesthesia

We have already emphasized various times the need to take certain hygienic measures before handling the vaginal prolapse. When it comes to repositioning of the prolapse a next point of attention arises: epidural anesthesia.

Naturally when a farmer decides to take matters into his own hands an epidural is not amongst the options. Veterinarians however do have the option to perform an epidural anesthesia before repositioning and this should be seriously considered. In many cases, even when deciding to simply reposition the vaginal prolapse without the intention to utilize a more permanent retention techniques, an epidural can be advised, as this does not only simplify the reposition, it also combats the direct reoccurrence of the vaginal prolapse.

In cows a caudal epidural is considered an easy and inexpensive method of analgesia. This form of anesthesia is thus commonly utilized for obstetric manipulations. In most cases and definitely in the case of an acute vaginal prolapse desensitization of the 3rd and 5th sacral nerve is sufficient and thus one will always opt for a low caudal epidural between the 1st and second coccygeal space. Ideally the hair dorsal to the site where one is planning on administering the anesthetic should be clipped and the skin scrubbed and disinfected. In order to locate the area between the 1st and 2nd coccygeal space the tail should be moved up and down. An 18 gauge needle is placed in the located fossa at a 45 degree angle and then pushed forward to penetrate the skin and enter the epidural space. Once the needle is in place the syringe may be attached and if no resistance is felt the anesthetic can be slowly injected. To determine whether the needle is placed correctly one may put a drop of anesthetic on it and observe whether it is drawn into the epidural space by negative pressure (Edmondson, 2008). The ability to inject through the needle without any pressure is by many considered sign enough that the needle is placed correctly. The dosage of local anesthetic to be used naturally depends upon the product, when using procaine 4% a 2 cc injection will for instance suffice.

In sheep an effective caudal analgesia can be realized by placing an epidural injection with xylazine and Lidocaine in between the sacrococcygeal articulation. Lidocaine alone can provide caudal analgesia for up to 4 hours following epidural injection, but when injecting too high volumes paresis and recumbence may result. Xylazine on the other hand has the capacity to desensitize sensory nerve fibers without effecting motor fibers to the same extend, hereby leaving the patient standing. Two milliliters of solution containing 0.07mg/kg xylazine and 0.5mg/kg of lidocaine is the recommended dosage to bring about caudal analgesia for approximately 24 hours (Scott et al., 1995). The sacrococcygeal articulation can be identified by slight vertical movement of the base of the tail. The

site must also be clipped and the skin scrubbed and disinfected. A 20 gauge needle may then be inserted at an angle of 20 degrees to the horizontal plane. The lack of contact with bone during needle insertion combined with the fact that there is no resistance to injection of the solution indicate the correct placements of the epidural (Scott, 1996).

Not only does the epidural combat straining in both sheep and cattle, it also desensitizes the perineal area and vulva lips making it possible to painlessly place a retention suture.

5.4.1.2 Retention Sutures

There are many different suture techniques that one may encounter in practice. With this said, there are few suture techniques that are considered good. The insertion of metal pins through the vulva lip, in any form shape or size is best to be avoided and the same goes for suturing closed the vulva with a diverse range of creative suture patterns. What is wrong with these techniques is that they penetrate the vulvar and/or vaginal mucosa. The combination of a mucosa penetrating wound with urine scalding and bacterial contamination will at its best lead to a mild infection but is more likely to lead to large diphtheritic areas that cause considerable discomfort and tenesmus (Scott, 2010).

In recent years the Buhner suture has proven itself by far the most secure method for the retainment of a vaginal prolapse in both cows and ewes. The procedure for placing such a suture is simple, the method is effective and the mucosa is left intact.

In case one we already described how to place a Buhner suture in a cow. After washing the involved tissues, placing an epidural and repositioning the vaginal prolapse a Buhner needle is inserted through the vulva. The needle enters the vulva through the fine-haired skin below and slightly lateral to the ventral commissure of the vulva and reappears at an equal distance above the dorsal vulvar commissure. It is important that the Buhner suture is placed sufficiently deep into the perivaginal tissue in order to give strength to the suture. After placing the needle, a piece of umbilical tape is placed through the loop eye of the needle and the needle is removed via the dorsal opening, hereby threading the umbilical tape through the full length of the right vulvar lip. The same course of action is then repeated, this time inserting the needle a little bit to the left of where the umbilical tape appeared above the dorsal vulvar commissure and ending underneath the ventral vulvar commissure. The result of the described procedure should be a circular suture that is best tightened to allow no more than two to three fingers to pass through the vulva opening.

A bowtie is made to facilitate an easy opening of the suture, making it unnecessary to redo the entire suture every time access to the vagina is required, for instance when needing to perform a vaginal exam.

The method described above is actually one of two traditional forms of the Buhner suture. When it comes to Buhner sutures we can in fact distinguish between a perivaginal totally imbedded closing or the perivaginal-percutaneous method. In the perivaginal-percutaneous method the knot present underneath the ventral vulvar commissure rests on a strip of intact skin. To achieve this it is important to make two small vertical incisions underneath the ventral vulva commissure several centimeters apart. A single horizontal incision is made above the dorsal vulvar commissure. The Buhner suture is then placed using the incisions as points of entrance and exit for the needle and umbilical tape.

In Case 1 the perivaginal-percutaneous method was applied as the suture was able to be opened and removed easily. The veterinarian however did not place any incisions through the vulvar skin before inserting the Buhner. A disadvantage of the perivaginal percutaneous method is that the suture is more in contact with the “outside world” and thus more susceptible to contamination.

The point of a perivaginal totally imbedded closing is that the knot of the suture is placed completely in the wound bed and is thus covered by skin. This method is slightly more resistant to bacterial contamination, but a veterinarian is required to remove the suture. The method is therefore best saved for non pregnant animals or animals that prolapse very early on during their pregnancy. The technique of placing the Buhner suture is for the most part identical to the one described above except for the fact that only 2 incisions are made prior to insertion of the needle. One horizontal incision is made dorsally to the dorsal vulva commissure and one horizontal incision is made ventral to the ventral vulva commissure. The Buhner needle must consequently be placed via these openings, hereby allowing the umbilical tape and its end knot to be fully imbedded into the wound bed (De Kruif and Van Soom, 2009).

Buhner sutures may be the best method for retaining a vaginal prolapse but they are not flawless, even properly placed Buhner stitches sometimes fail. The most common cause for this failure is that the retention stitch rips through the dorsal vestibular or vaginal wall (Pitmann 2010). By incorporating a horizontal mattress-like suture into the Buhner suture Pittman suggest that the downwards tension on the dorsal vestibular area during straining is redirected towards thicker tissues and hereby accounts for reduced stitch failure. In order to place such a modified Buhner suture one first places the needle above and lateral to the dorsal commissure of the vulva and directs it horizontally, from one side of the vulva to the other hereby penetrating the perineal body. One must be cautious as not to penetrate the rectum or vaginal vaults. After this the umbilical tape is inserted into the needle eye and the needle is withdrawn through the entry port.

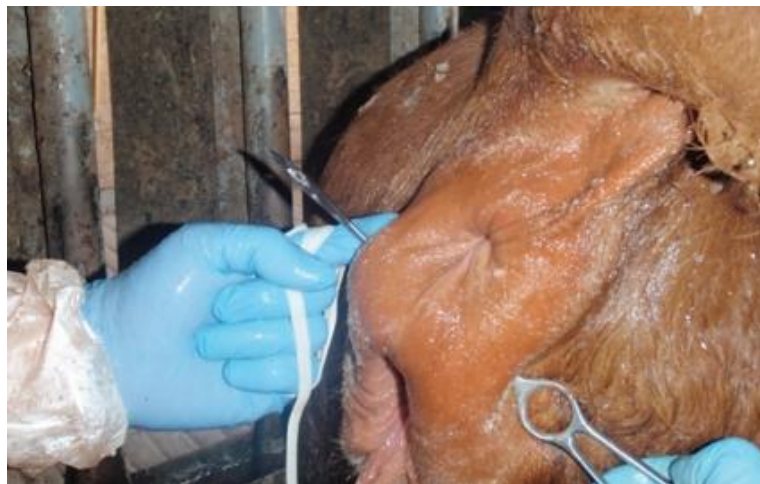

Figure 20: Step one in creating a modified Buhner suture (Pittman, 2010)

The second port of entrance is made in the fine haired-skin below and slightly lateral to the ventral commissure. The needle is directed dorsally and subcutaneously along the lateral side of the vulvar

lip, exiting about 2cm below the exit port of the horizontal placed suture. The umbilical tape already inserted dorsally through the vulva is now passed through the needle and the needle is removed. The same procedure is repeated for the contralateral side of the vulva. The bottom ends of tape are then tensed to fit no more than two fingers and a bowtie is made.

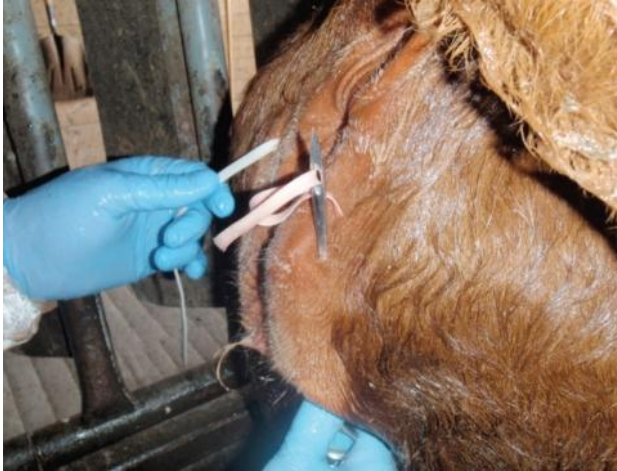

Figure 21: Step two and three (Pitmann, 2010)

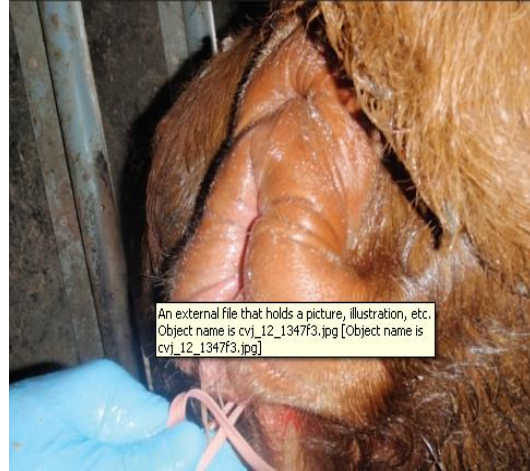

Figure 22: The end result (Pitmann, 2010)

Placing a Buhner suture will naturally bring about some swelling of the vulvar and perineal area. Other complications such as extreme edema, cellulitis, pain and straining, urine pooling and phlegmons can on occasion also be witnessed. To minimize the chance of infection it is advisable to soak the umbilical tape in a mild antiseptic or to cover it with antibiotics.

In sheep a standard Buhner suture is placed exactly as described above and in case 1, naturally the materials are of a smaller format, but the protocol remains the same. The Buhner suture is tightened to one finger diameter.

Sheep and cattle that have suffered a vaginal prolapse are inclined to do so again, it is therefore advisable to undergo no further reproductive escapades with them (Scott, 2010 and Wolfe, 2009).

5.4.2 Chronic Vaginal Prolapse

In the case of an acute vaginal prolapse, temporary retention measures usually suffice. A chronic vaginal prolapse however requires more invasive techniques to stabilize the vagina.

In cows suffering a vaginal prolapse that is associated with excessive redundancy of the dorsal vaginal wall a Johnson button or alternatively a Minchev suture may be placed. In the case of a Johnson button an indwelling needle is placed from the dorsolateral vaginal wall through the sacrotuberous ligament, gluteal musculature and skin. After the device is inserted, large flat disks are attached to each end to secure the device. When using the Minchev retention technique an umbilical tape suture is placed again from the dorsolateral vaginal wall through the sacrotuberous ligament, gluteal musculature and skin. With the Minchev suture, rolls of gauze sponges are attached to each end to secure the device. Both the Johnson button and Minchev suture must remain in place for 2 to 6 weeks to allow for the formation of elaborate fibrous adhesions to secure the vagina. The procedure is best performed on both sides of the animal. Unfortunately both techniques are rather traumatic and may

lead to tearing of the vagina into the abdomen due to chronic straining after surgery. If the pudendal artery of the sciatic nerve are not avoided during surgery they may also be permanently damaged (Miesner and Anderson, 2008).

When it is mainly the ventral vaginal wall that shows excessive redundancy one may opt to perform a cervicopexy . A cervicopexy results in the fixation of the external os of the cervix to the prepubic tendon. The procedure can be carried out either via a flank laparotomy or via a vaginal approach. Although a flank laparotomy allows for the cervix to be more accurately anchored, transvaginal cervicopexy offers the easiest and least invasive surgical approach (Miesner and Anderson, 2008). The transvaginal cervicoplasty is carried out after the administration of a small caudal epidural. The needle with attached suture material is carried into the vagina by hand. Via palpation one can locate the prepubic tendon just cranial to the pelvic symphysis. One must then locate the urethra and bladder, to ensure placement of the suture lateral to these structures to insure accurate location of these structures it may be useful to place a catheter. The needle point is directed through the floor of the vagina below and a little bit to the right of the vaginal end of the cervix, the needle is then traditionally directed back up through a triangular area formed by a short band of the pepubic tendon. Hereafter the needle is passed through the prepubic tendon and vaginal floor back into the vaginal lumen. To avoid breaking of the needle it can however be advised to first pass the needle down through the prepubic tendon in a medial to lateral direction and then through the triangular area and back into the vaginal lumen via the vaginal floor.

The needle is then inserted from left to right through the ventral intravaginal part of the cervix, care must be taken not to penetrate the cervical lumen. The ends of the suture are then tied and a second suture is applied on the other side (Turner and McIlwraith, 1989).

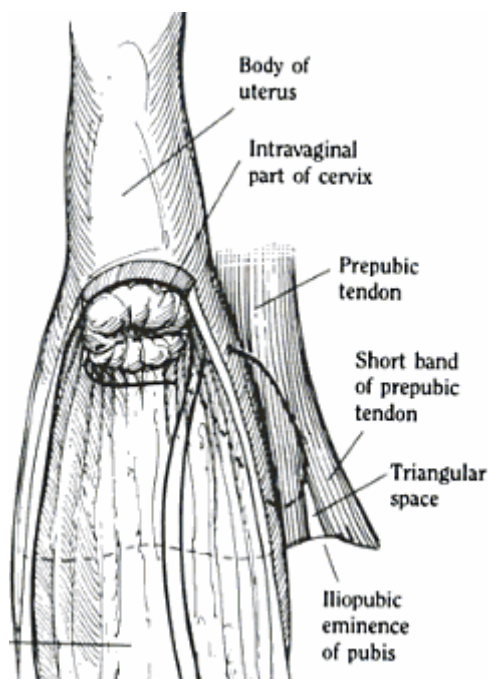


Figure 23: Modified Cervicopexy
(Turner and McIlwraith, 1989)

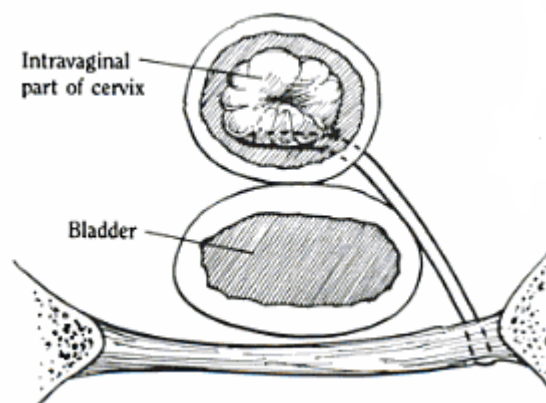


Figure24: Modified Cervicopexy
(Turner and McIlwraith, 1989)

Disadvantages associated with cervicopexy include entrapment of the urethra, bladder or intestines, increased risk for bacterial infection, compromise of the cervical lumen and suboptimal positioning of the vagina (Miesner and Anderson, 2008).

Vaginoplasty and vaginal resection are effective methods for combating vaginal prolapse and they may be applied to both dorsal and ventral wall prolapse (Miesner and Anderson, 2008). As with all the techniques discussed previously these techniques are also carried out on the standing animal, after placing of a small epidural. In the case of a vaginoplasty a triangular segment of the dorsolateral wall is removed on both sides, with the base of the triangle facing the dorsal midline. The sides are then sutured together. This method although effective in combating vaginal prolapse, makes the animal unsuitable for natural servicing and delivery.

When performing a vaginal resection, a complete segment of the vagina is generally removed. A vaginal speculum is inserted into the lumen of the prolapsed vagina and pins are placed through the vaginal prolapse to stabilize it for surgery. The injured portion of the prolapse is then removed and an end to end anastomosis is performed. The procedure can be compared to a rectum amputation. Complications such as stricture, dehiscence, bleedings and abscesses are not uncommon. Once again the patient is made unfit for natural servicing and delivery.

In sheep one can apply methods such as the Minchev suture, or Johnson button, but this is hardly ever done. Realistically speaking, chronic vaginal prolapses in both cattle and sheep are usually not treated, instead the affected animals are culled.

6. Conclusion

When it comes to the causes of vaginal prolapse there is still a lot that remains unknown. Although there are plenty of theories regarding the cause of vaginal prolapse, the scientific evidence supporting these theories is frequently lacking. Newfound insight concerning the altered metabolism of collagen in patients suffering from a vaginal prolapse, is probably the beginning of a more concrete scientific understanding of the pathology.

With respect to the treatment of vaginal prolapse there are a lot of alternatives, nevertheless I find that there are only a few good options.

Strictly speaking the management of vaginal prolapse in both cows and ewes can be narrowed down to a few basic steps: assessment, replacement and retention. All these steps should be undertaken swiftly but only after instigating the appropriate hygienic measures. Additionally I believe that an epidural ought to be utilized when replacing a vaginal prolapse of any significance. When it comes to retaining the vaginal prolapse an acute vaginal prolapse should be combated with either a noninvasive retention method, such as a Dalton spoon or a harness, or if more thorough measures are necessary a Buhner suture should be placed. A chronic vaginal prolapse is best not treated, unless of course this is specially requested by the owner. Naturally in practice every case is unique and thus every case should be approached with an open mind and a healthy dose of logic.

References

- Adams, N. R. 1990. Permanent infertility in ewes exposed to plant oestrogens. *Australian Veterinary Journal* 67, 197.
- Adams N.R. and Saunders M.R. (1993). Development of uterus-like redifferentiation in the cervix of the ewe after exposure to estradiol-17 beta. *Biology of Reproduction*. 48(2), 357-362.
- Adams N.R. (1995). Detection of the effects of phytoestrogens on sheep and cattle. *Journal of Animal Science* 73, 1509-1515.
- Anonymous. (2010). *Vervoerder van Dieren*. Course Dierengezondheidszorg, Drogen, p15.
- Adlercreutz H., Honjo H., Higashi A., Fotsis T., Hamalainen E., Hasegawa T., Okada H. (1991). Urinary excretion of lignans and isoflavonoid phytoestrogens in Japanese men and women consuming a traditional Japanese diet. *Journal of Clinical Nutrition* 54, 1093.
- Anderson J.J.B., Anthony M., Messina M., Garner S.C. (1999). Effects of phyto-oestrogens on tissues. *Nutrition Research Reviews* 12, 75–116.
- Budras K.D. and Habel R.E. (2003). Perineum, Pelvic Diaphragm, Ischioanal fossa and Tail. In: Budras K.D (editor). *Bovine anatomy*. Schlutersche, Hannover, Germany, p. 92-96.
- Clark I.M., Powell L.K., Cawston T.E. (1994). Tissue inhibitor of metalloproteinases (TIMP-1) stimulates the secretion of collagenase from human skin fibroblast. *Biochemical and Biophysical research communications* 203, 874-880.
- Croubels S. and De Backer P. (2009) *Diergeneeskundige Toxicologie*. Course faculty of veterinary medicine, Ghent, 185.
- De Kruif A. and Van Soom A.(2009). *Verloskunde van de Huisdier 2*. Course faculty of veterinary medicine, Ghent.
- Deprez P. (2009). *Propedeutica van de grote huisdieren*. Course Faculty of Veterinary Medicine, Ghent.
- Drost M. (2007). Complications during gestation in the cow. *Theriogenology* 68, 487-491.
- Edmondson M.A (2008). Local and Regional Anesthesia in Cattle. *Veterinary Clinics Food Animal Practice* 24, 211-226.

- Ennen S., Kloss S., Scheiner-Bobis G., Failing K., Wehrend A. (2011). Histological, hormonal and biomolecular analysis of the pathogenesis of ovine Prolapsus vaginae ante partum. *Theriogenology* 75, 212-219.
- Folman Y. and Pope G.S. (1966). The interaction in the immature mouse of potent oestrogens with coumestrol, genistein and other uterovagintrophic compounds of low potency. *Journal of Endocrinology* 34, 215.
- Fylling Petter. (1970). The effect of pregnancy, ovariectomy and parturition on plasma progesterone level in sheep. *Acta Endocrinologica*, 65(2), 273-283.
- Hafez E.S.E. and Hafez B. (2000). Gestation, Prenatal physiology and Parturition. In: Balado D. (editor) *Reproduction of Farm Animals*. 7th edition, Williams & Wilkins, Maryland, USA, p 141.
- Henricks D.M., Dickey J.F., Hill J.R., Johnston W.E. (2011). Plasma Estrogen and Progesterone Levels After Mating, and During Late Pregnancy and Postpartum in Cows. *Endocrinology* 90(5), 1336-1342.
- Hosie B. (1989). Vaginal prolapse and rupture in sheep. In *Practice* 11(5), 215-218.
- Hosie B.D., Low J.C., Bradley H.K., Robb J. (1991). Nutritional factors associated with vaginal prolapse in ewes. *Veterinary Record* 128, 204-208.
- Hunnam J.C., Parkinson T.K., McDougall S. (2009). Transcutaneous ultrasound over the right flank to diagnose mid- to late-pregnancy in the dairy cow. *Australian Veterinary Journal* 87(8), 313-317.
- Intervet International. (2011). Pregnancy diagnosis in heifers and cows. Internet reference: <http://www.partners-in-reproduction.com/reproduction-cattle/pregnancy-diagnosis.asp> (consulted on the 20th of March 2011).
- Jack G.S., Nikolova G., Vilain E., Raz S., Rodriguez L.V. (2005). Familiar transmission of genitovaginal prolapse. *International Urogynecology Journal* 17(5), 498-501.
- Jeffrey J.J. (1991) Collagen and collagenase: Pregnancy and parturition. *Seminars in Perinatology* 15, 118-126.
- Kahn C. ed. *Merck veterinary manual*. 9th ed. Rahway, NJ: Merck, 2005.
- Kambadur R., Sharma M., Smith T.P.L., Bass J.J. (1997). Mutations in myostatin (GDF8) in Double-Musled Belgian Blue and Piedmontese Cattle. *Genome Research* 7, 910-915.
- König H.E. and Liebich H.G. (2004). Female Genital Organs. In: König H.E. and Liebich H.G. (editors) *Veterinary Anatomy of Domestic Mammals*. First edition, Schattauer, Stuttgart, Germany. p. 407-413.

Kroeze C.J and De Vries C.J. (2008). VWA toelichting op de transportverordening en de hygiene verordeningen en de gevolgen voor de noodslachting van als landbouwhuisdier gehouden hoefdieren. Internet reference: www.vwa.nl (consulted on the 30th of march 2011).

Lammoglia M.A., Bellows R.A., Short R.E., Bellows S.E., Bighorn E.G., Stevenson J.S., Randel R.D. (1997). Body Temperature and Endocrine Interactions Before and After Calving in Beef Cows. *Journal of Animal Science* 75, 2526-2534.

Lightfoot R. J., Croker K.P., Neil H.G. (1967). Failure of sperm transport in relation to ewe infertility following prolonged grazing on oestrogenic pastures. *Australian Journal of Agricultural Research* 18, 755.

Lloyd A.L. (2011) Effect of relaxin on parturition in ruminants. Internet reference: <http://www.extension.iastate.edu/Pages/ansci/beefreports/asl-1465.pdf> (consulted on april 2nd 2011).

Low J.C. and Sutherland H.K (1987). A census of the prevalence of vaginal prolapse in sheep flocks in the Borders region of Scotland. *The Veterinary Record* 120(24), 571-575.

Miesner M.D., Anderson D.E., (2008). Management of Uterine and Vaginal Prolapse in the Bovine. *Veterinary Clinics Food Animal Practice* 24, 409-419.

Olsen B.R. and Ninomiya Y. (1999). Fibrillar collagens. In: Kreis T. and Vale R. (editors) *Guidebook to the extracellular matrix, anchor and adhesion proteins*. Sambrook and Tooze Publications at Oxford University Press, Oxford, UK, p. 383-387.

Ososki A. L. and Kennelly E. J. (2003). Phytoestrogens: a review of the present state of research. *Phytotherapy Research* 17, 845–869.

Osinga A. (1978). Endocrine aspects of bovine dystocia with special reference to estrogens. *Theriogenology* 10 (2-3), 149-166.

Pelzer D.K. (2008). Vaginal Prolapse. Internet reference: <http://www.danekeclublambs.com/VaginalProlapse.html> (Consulted on April 5th 2011).

Pittman T. (2010). Practice Tips. *Canadian Veterinary Journal* 51(12), 1347-1348.

Powell J. (2005). *Livestock Health Series: Reproductive Prolapses of Cattle*. Fact Sheet # FSA 3102. Arkansas Cooperative Extension Service, Little Rock, AR. 7-05.

Pugh D.G. (2002). *Theriogenology of Sheep and Goats*. In: Schreffer J. A. (editor) *Sheep and Goat Medicine*. first edition, Saunders, Philadelphia, USA, p. 173.

Purohit G. (2010). *Methodes of Pregnancy Diagnosis in Domestic Animals: the Current Status*. WebmedCentral REPRODUCTION 2010;1(12):WMC001305

Purohit G. (2010). *Parturition in Domestic Animals: A Review*. WebmedCentral REPRODUCTION 2010;1(10):WMC00748

- Rexroad C.E., Casida L.E., Tyler W.J. (1974). Crown-Rump Length in Purebred Holstein-Friesian Cows. *Journal of Dairy Science* 57(3), 346-347.
- Riding G.A., Lehnert S.A., French A.J., Hill J.R. (2007) Conceptus-related measurements during the first trimester of bovine pregnancy. *The Veterinary Journal* 175, 266-272.
- Samual C.S., Coghlan J.P., Bateman J.F. (1998). Effects of relaxin, pregnancy and parturition on collagen metabolism in the rat public symphysis. *Journal of Endocrinology* 159, 117-125.
- Scott P. (1996). Caudal analgesia in sheep. *In Practice* 18, 383-384.
- Scott P.R. (2010) *Sheep Medicine*. Mason publishing Ltd, London.
- Scott P. and Gessert M.(1998). Management of ovine vaginal prolapse. *In Practice* 20(1), 28-34.
- Scott P.R., Sargison N.D., Penny C.D., and Strachan W.D. (1995). The Use of Combined Xylazine and Lignocaine epidural injection in ewes with vaginal or uterine prolapses. *Theriogenology* 43, 1175-1178.
- Sherwood O.D., Crnekovic V.E. (1979). Development of a homologous radioimmunoassay for rat relaxin. *Journal of Endocrinology* 104, 893–897.
- Sherwood O.D., Crnekovic V.E., Gordon .W.L., Rutherford J.E. (1980). Radioimmunoassay of relaxin throughout pregnancy and during parturition in the rat. *Journal of Endocrinology* 107, 691–698.
- Sjaastad O., Hove K., Sand O. (2003). The Kidneys and the Urinary Tract. In: Steel C. (editor) *Physiology of Domestic Animals*. First edition, Gummerus printing, Finland, p. 447.
- Söderberg, M. W., Falcone C., Byström B., Malmström A., Ekman G. (2004). Young women with genital prolapse have a low collagen concentration. *Acta Obstetrica et Gynecologica Scandinavica*, 83, 1193–1198.
- Stouw C.J. (2011). Zwartbleschaap. Internet reference: www.zwartbleschaap.nl (consulted on the 31st of March 2011).
- Tandon B. (2004) Abortion in Dairy Cows New Insights and Economic Impacts. *Vetcare Update Bulletin* 12(2) 4.
- Thomas M., Langley B., Berry C., Sharma M., Kirk S., Bass J., Kambadur R. (2000). Myostatin, a Negative Regulator of Muscle Broth, Functions by Inhibiting Myoblast Proliferation. *The Journal of Biological Chemistry* 275, 40235-40243.
- Timmermans J.P.(2005). *Cel en Weefselleer 1*. Course, Faculty of Veterinarian Medicine, Antwerp.

Turner S.A. and McIlwraith W.C. (1989). Cervicopexy For Vaginal Prolapse. In: Turner S.A and McIlwraith W.C. (editors) Techniques in Large Animal Surgery. Second edition, Lippincott Williams & Wilkins, Philadelphia, USA, p.330-333.

Twiss C., Triaca V., Bergman J., Rodriguez L.V. (2007). The epidemiology, social burden, and genetics of pelvic organ prolapse. Current Bladder Dysfunction Reports 3(2), 90-94.

Twiss C., Triaca V., Rodriguez V.L. (2007) Familial transmission of urogenital prolapse and incontinence. Current Opinion in Obstetrics & Gynecology 19(5) 464-468.

Umburger H.S. (1991). Feeding Sheep. Virginia Cooperative Extension Publication, USA, 410-853.

Veeraiah G., Srinivas M. (2010). Spontaneous extrusion of the intestines and uterus as a sequel to vaginal prolapse in a buffalo heifer: a case report. Buffalo Bulletin 29(1), 60-64.

Weber E. (1910) Beobachtung über die rektaltemperatur des gesunden rindes, zugleich ein beitrage zur frage der vorausbestimmung der zeit der geburt bei der kuh. Dtsch. Tierärztl. Wochenschr. 18, 143.

Woclawek-Potocka I., Okuda K., Acosta T.J., Korzekwa A., Pilawski W., Skarzynska D.J. (2005). Phytoestrogen metabolites are much more active than phytoestrogens themselves in increasing prostaglandin F_{2α} synthesis via prostaglanin F_{2α} synthase-like 2 stimulation in bovine endometrium. Prostaglandins and other Lipid Mediators 78(1-4), 202-217.

Woclawek-Potocka I., Acosta T.J., Korzekwa A., Bah M.M., Shibaya M., Okuda K., Skarzynski D.J. (2005). Phytoestrogens modulate prostaglandin production in bovine endometrium: cell type specificity and intracellular mechanisms. Experimental Biology and Medicine 230, 366-333.

Wolfe D.F. (2009) Medical and Surgical Management of Vaginal Prolapse in Cattle. Presentation "81st western veterinary conference", Auburn, Februari 15th 2009.

Wolfe D.F. and Carson R.L. (1999). Surgery of the vestibule, vagina, and cervix: cattle, sheep and goats. In: Wolfe D.F. and Moll H.D. (editors) Large animal urogenital surgery. 1st edition, Williams and Wilkins, Baltimore, USA, p. 421-424.