

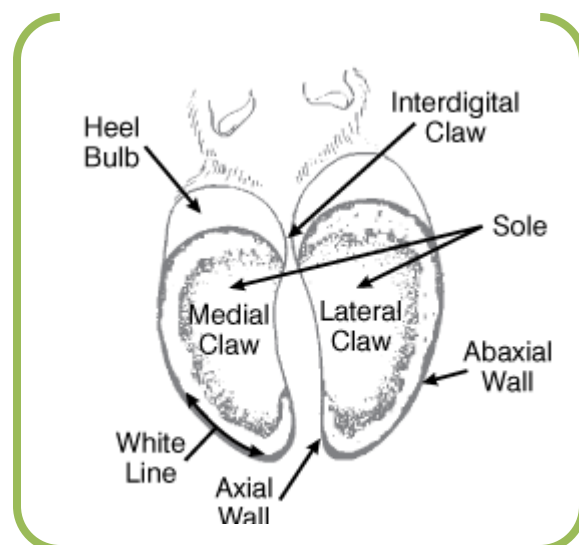
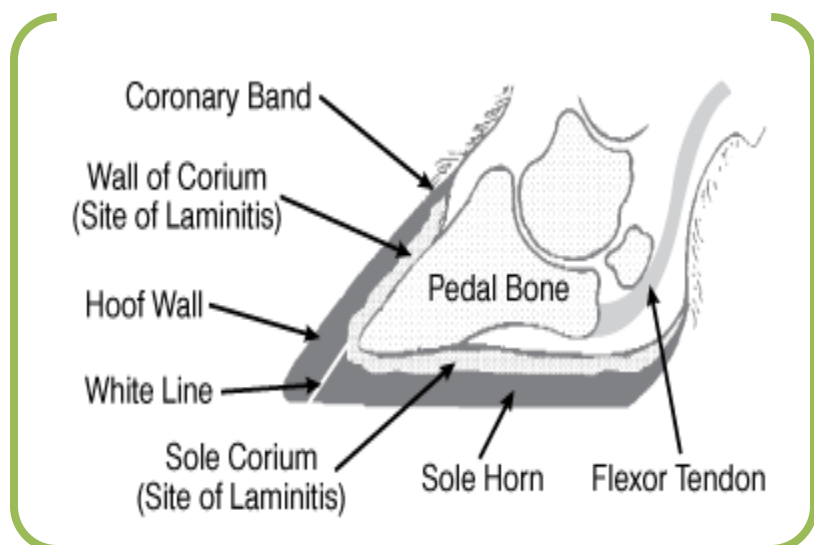
Doctor J HOOF CARE

*"Serving Manitoba Dairy,
Farms for over 20 years"*



Anatomy

The hoof grows from the coronary band at a rate of 1/4 inch per month. The hoof is composed of the outer wall, white line, sole and heels. The outer claw of the rear foot grows faster than the inner claw; the inner claw grows faster on the front foot. It is important for the wall to withstand stress yet be able to move slightly in order to function as a shock absorber. The heel (bulb) responds to stress and weight by compression.



The laminae help reduce the impact within the hoof wall. The laminae (structures within the hoof that look like slanting lines or fish gills) are part of the corium which is rich in blood vessels and nerves. The corium (or quick) is positioned between the foot bone and the hoof wall; it is vulnerable to inflammation which leads to swelling causing pressure, pain, and tissue damage in the corium (laminitis). On the underside of the foot, the sole is formed by the corium, and the junction of the hoof wall and sole is seen as a white line. The softer tissue at the white line is a weak spot in the hoof that is subject to penetration by stones or grit.

The corium produces the hoof horn and sole. The healthier the corium, the better the hoof horn produced. Diseases such as laminitis reduce the integrity of hoof horn formed and do not protect the foot or support the body weight as well. Beneath the corium lies the pedal (coffin) bone. The pedal bone is surrounded by and

suspended within the corium. The pedal bone is separated from the hoof wall by a very thin layer of corium. It is very easy for the pedal bone to pinch the blood vessels and nerves of the corium when too much pressure is placed on the heels.

Understanding the Anatomy of Cows Hooves

by Dr. Luis Rodriguez, Dr. Jeff DeFrain

In a previous column, we discussed the reasons for routine evaluation and trimming of a cow's foot in order to properly maintain the weight-bearing surface of the hoof (claw). To better understand the importance of a balanced, weight-bearing surface, it is important to understand the basic anatomy of the foot.

Anatomical features

To begin, let's focus on the internal anatomical features of the foot ([Figure 1](#)). The foot of the cow contains the portion of the limb below the fetlock joint and would be similar to our fingers and toes.

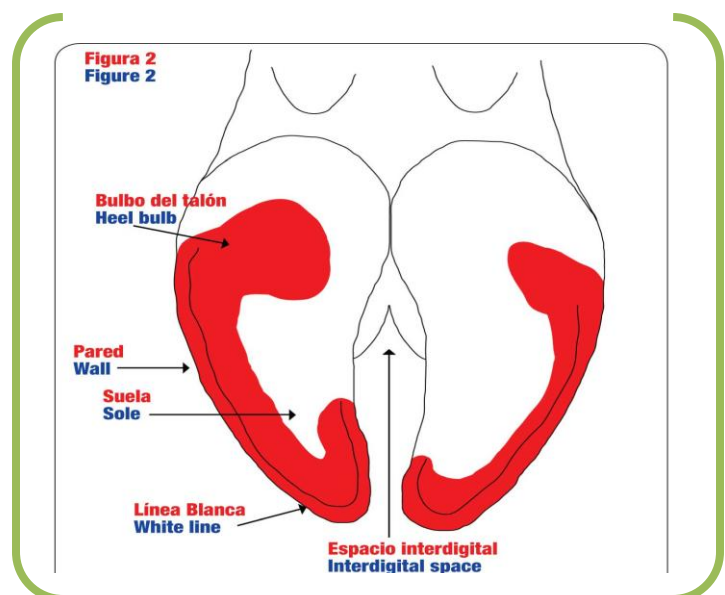
A cow's foot is comprised of two digits (toes) that are protected by the horn-covered claw capsule. Each of the digits contains four bones: phalanx 1 (P1; not shown in the figures), phalanx 2 (P2), phalanx 3 (P3), and the navicular bone (NB). All of these bones serve as support structures for the leg and the rest of the body. The remaining internal components of the foot include:

- Corium: nerve and blood supply to the horn-producing areas of the hoof.
- Digital cushion: tissues that function like an elastic shock absorber between P3 and the corium, and as a pump that transports blood back up the leg as the cow walks.
- Lamellae: strong fibers that attach the wall to P3.

Claw Surface

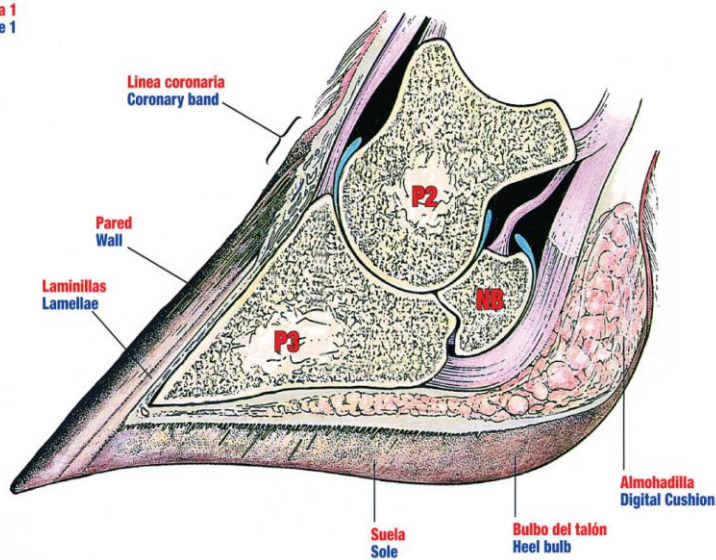
Now let's look at the components of the claw surface as it would be viewed during a claw examination and/or trim

([Figure 2](#)). The weight-bearing surface is shaded in red and consists of the heel bulb, wall and sole. Components of the claw surface include:



- Heel bulb: composed of soft, rubbery horn originating from the same horn found within the coronary band (shown in Figure 1).

Figura 1
Figure 1



- Wall: consists of very tough, tubular horn and is smooth and shiny; however, faint ridges can be found running parallel to the coronary band.
- Sole: ideally one inch thick at the tip of the toe, becoming thicker towards the bulb.
- White line: the softest horn within the claw, providing flexibility between the harder horn of the wall and the softer horn of the sole.
- Interdigital space: the skin and tissue separating the two claws.

It is important to remember that cattle stand “in” their feet and not “on” them. As you’ll note in Figure 1, P3 is suspended within the claw horn capsule by the laminar corium and collagen fiber bundles. This type of attachment ensures that the weight is transferred from P3 onto the hoof wall when the cow walks and the foot is placed on the walking surface.

Knowing the anatomical features of the foot and claw will help you better understand the foundation necessary for improving hoof health on the dairy. In the months ahead, we will be discussing functional trimming procedures, the identification of claw lesions and the factors that cause them

One of the best ways to understand the diseases that occur in the hoof is to first learn about basic hoof anatomy. There are a variety of causes of lameness that occur in a variety of areas around the hoof - some can be prevented with a footbath and others are better treated through nutritional adjustments. It is important to understand the source of hoof ailments, and where they are occurring on the hoof in order to provide the best solution to the lameness problem.

Figure 1: Claw Bones and Tendons

Coronary Band: The coronary band is normally soft and shiny and may be pink in color. **Wall:** The wall is smooth and shiny. Faint ridges run parallel to the coronary band. The wall consists of very tough tubular horn. **Bulb:** The bulb is continuous with the coronary band and is composed of soft, rubbery horn.

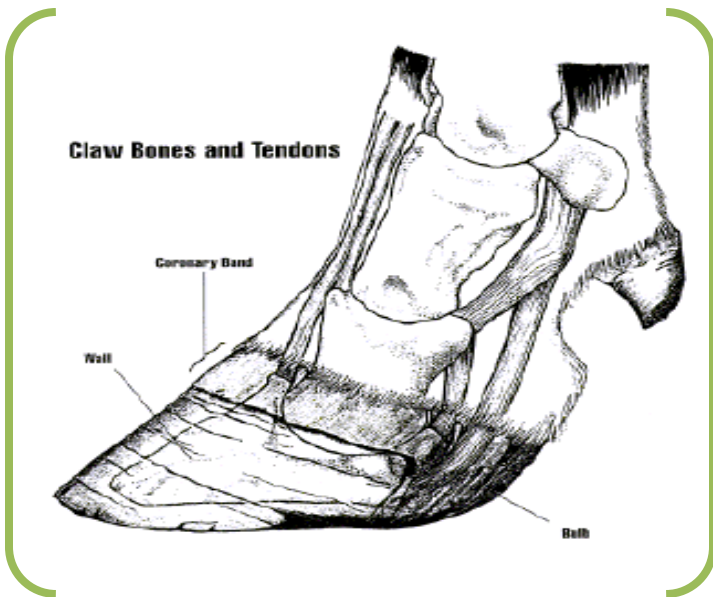
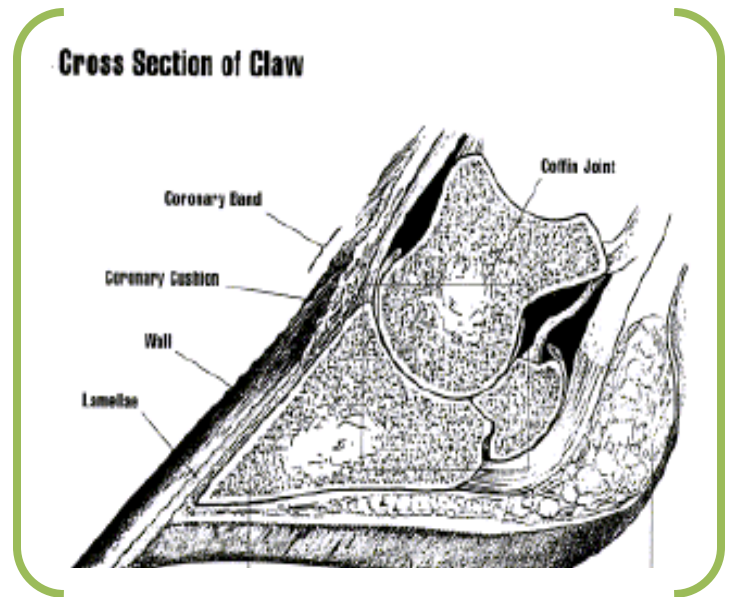
Coronary Band. Area at the top of the hoof that is normally soft and shiny, and may be pink in color.

Wall. Consists of tough tubular horn that's smooth and shiny, with faint ridges running parallel to the coronary band.

Bulb. Back part of hoof continuous with coronary band, composed of soft rubbery horn.

Coronary Cushion. Mass of elastic tissue and veins beneath the coronary band; when the ox exercises, the cushion pumps blood through the foot back into the body.

Lamellae. Hundreds of tiny ridges attached to the coffin bone by strong fibers and covered by the lower part of the inside wall.



Coffin Bone. Triangular bone at the end of the digit.

Digit. Toe; two digits make up the foot.

Sole. Concave bottom of the hoof, thicker towards the heel and sloping away from the outside wall.

Digital Cushion. Area within the bulb; functions as an elastic shock absorber and also may work as a pump to force blood back up the limb as the ox walks.

Heel. Bulb and digital cushion.

Figure 2. Cross Section of Claw

Coronary Cushion: Beneath the coronary band is the coronary cushion, a mass of elastic tissue and veins. When the animal exercises, the cushion pumps blood through the foot and back into the body. **Lamellae:** The lower part of the inside wall covers hundreds of tiny ridges to the coffin bone. **Coffin Bone:** The triangular bone at the end of the digit. **Sole:** The sole is thicker towards the heel, slopes away from the outside wall, and is concave. **Digital Cushion:** Inside the bulb is the digital cushion. The cushion functions as an elastic shock absorber. It also may work as a pump to force blood back up the limb as the animal walks.